

CASE REPORT

# Fatal pneumonia and empyema thoracis caused by imipenem-resistant *Nocardia abscessus* in a cancer patient



Chih-Cheng Lai <sup>a</sup>, Hsih-Yeh Tsai <sup>b,c</sup>, Sheng-Yuan Ruan <sup>b</sup>,  
Chun-Hsing Liao <sup>c</sup>, Po-Ren Hsueh <sup>b,d,\*</sup>

<sup>a</sup> Department of Intensive Care Medicine, Chi-Mei Medical Center, Liouying, Tainan, Taiwan

<sup>b</sup> Department of Internal Medicine, National Taiwan University Hospital, Taipei, Taiwan

<sup>c</sup> Department of Internal Medicine, Far Eastern Memorial Hospital, New Taipei City, Taiwan

<sup>d</sup> Department of Laboratory Medicine, National Taiwan University Hospital, National Taiwan University, College of Medicine, Taipei, Taiwan

Received 6 November 2012; received in revised form 21 December 2012; accepted 22 January 2013  
Available online 21 March 2013

## KEYWORDS

Empyema thoracis;  
Imipenem-resistant;  
*Nocardia abscessus*;  
16S rRNA sequencing

We describe a case of pneumonia and empyema thoracis caused by trimethoprim–sulfamethoxazole-susceptible, but imipenem-resistant *Nocardia abscessus* in a cancer patient. The isolate was confirmed to the species level by 16S rRNA sequencing analysis. The patient did not respond to antibiotic therapy, including ceftriaxone and imipenem, and died of progressing pneumonia and multiple organ failure.

Copyright © 2013, Taiwan Society of Microbiology. Published by Elsevier Taiwan LLC. All rights reserved.

## Introduction

The incidence of local and disseminated infections due to *Nocardia* species is increasing, especially in immunocompromised

individuals.<sup>1–4</sup> The most common risk factors for acquiring *Nocardia* infections include long-term steroid usage, neoplastic disease, and human immunodeficiency virus infection.<sup>4–6</sup> Advanced molecular methods such as polymerase chain reaction restriction enzyme analysis and 16S rRNA sequencing have resulted in the identification of a number of new species of the genus *Nocardia* in recent years.<sup>1</sup> Clinically, accurate identification of isolates beyond the genus level is essential because strains of *Nocardia* species can differ in the clinical presentations of nocardiosis and in resistance patterns to antibiotics.<sup>4,7</sup>

\* Corresponding author. Departments of Laboratory Medicine and Internal Medicine, National Taiwan University Hospital, 7 Chung-Shan South Road, Taipei, Taiwan.

E-mail address: [hsporen@ntu.edu.tw](mailto:hsporen@ntu.edu.tw) (P.-R. Hsueh).

*N. abscessus* was first proposed as a new species by Yassin et al in 2001<sup>8</sup>; however, little is known about its clinical significance. We describe a case of empyema thoracis due to *N. abscessus* in a cancer patient.

## Case report

A 54-year-old man had a medical history of angiosarcoma status after five courses of doxorubicin, and undergoing chemotherapy with paclitaxel. Six months prior to admission, he received video-assisted thoracoscopic surgery for diagnosis of a right middle lobe mass, which was proved to be metastatic angiosarcoma. The patient presented to the hospital with a 1-week history of mild respiratory distress, chest pain, fever, and purulent discharge from the video-assisted thoracoscopic surgery incision site on the right lower chest wall.

Physical examination revealed a body temperature of 38.6°C, a pulse rate of 112/min, a respiratory rate of 25/min, and a blood pressure of 125/73 mmHg. Coarse crackles were heard in both lung fields, but were more prominent in the right lower lung. Laboratory studies disclosed the following values: white blood cell count,  $16.49 \times 10^9/L$  with neutrophil predominance (92%); serum urea nitrogen, 190 mg/L; serum creatinine, 5.8 mg/L; alanine aminotransferase, 18 U/L; sodium, 130 mM; and C-reactive protein, 93 mg/L (reference value, <8.0 mg/L). Chest radiography showed multiple nodules and patchy infiltrations in both lungs, although they were more obvious at the base of the right lung (Fig. 1A).

Ceftriaxone was administered after collecting pus and sputum cultures. Because of the poor condition of the wound, the wound was debrided and a chest tube was inserted for drainage of pleural effusion that was detected by chest sonography. A diagnosis of empyema thoracis was made based on demonstration of frank pus upon pleural fluid aspiration. The clinical condition of the patient, however, gradually deteriorated and eventually resulted in acute respiratory failure with shock. The patient was

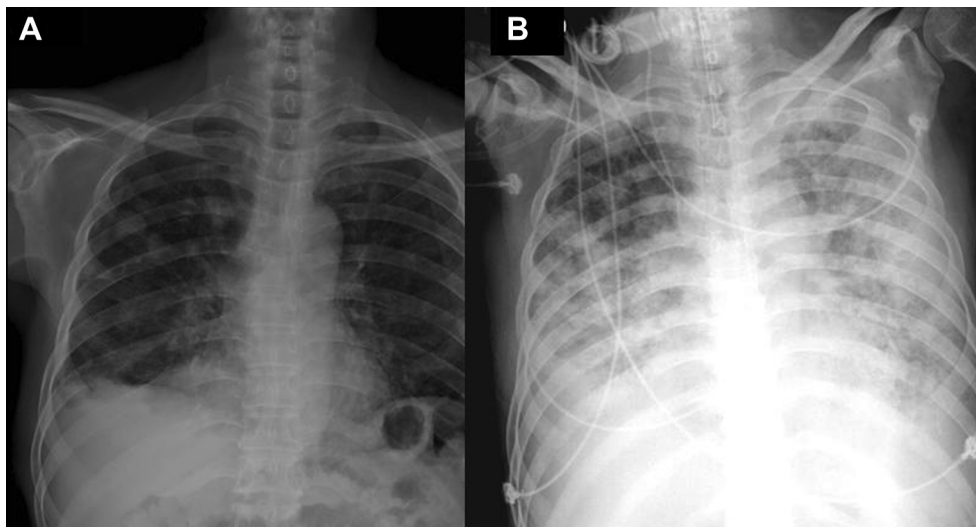
intubated because of hypoxemic respiratory failure and admitted to the intensive care unit.

Microbiological staining of the pus and pleural fluid specimens both disclosed Gram-positive branching bacilli and acid-fast bacilli (by modified acid-fast stain). Cultures of sputum, pus, and pleural effusion cultures all grew Gram-positive bacilli with beaded branching filaments and weakly acid-fast rods after incubation for 3 days, suggesting the presence of *Nocardia* species. In addition, the isolates were unable to hydrolyze casein, xanthine, hypoxanthine, or tyrosine. Ceftriaxone was switched to imipenem/cilastatin to expand the coverage of probably concurrently encountered nosocomial copathogens and *Nocardia* spp. However, the patient's condition continued to deteriorate. Follow-up of chest radiography revealed progressive patchy infiltrations bilaterally (Fig. 1B). The patient demonstrated symptoms and signs of multiple organ failure and died on the 20th hospitalization day.

The isolate was confirmed to be *N. abscessus* [GenBank accession number GU471235.1; maximal identity, 100% (564/564)] by 16S rRNA gene sequence analysis as reported previously.<sup>4,7</sup> The minimum inhibitory concentration (MIC) was 4.0 µg/L for trimethoprim–sulfamethoxazole, >32 mg/L for both ciprofloxacin and imipenem, and 1.5 mg/L for ceftriaxone as determined by the E-test (AB Biodisk, Solna, Sweden).

## Discussion

The clinical manifestations of infections caused by *N. abscessus* include respiratory tract infection, primary cutaneous infection, pericarditis, cerebral abscess, ocular infection, and disseminated infection.<sup>2,9–16</sup> In a previously reported multicenter study of the clinical presentations of infections due to various *Nocardia* species during a 13-year period in Taiwan,<sup>4</sup> one case of *N. abscessus*-related brain abscess was identified. In the present report, we used conventional biochemical studies and molecular methods to



**Figure 1.** Chest radiography showing (A) multiple nodules and bilateral patchy infiltrations, especially at the base of the right lung on admission, and (B) progressive patchy infiltrations over bilateral lung fields on the day of death (20th hospitalization day).

confirm that the empyema thoracis and pulmonary infection in our patient were due to *N. abscessus*.

Previous studies have demonstrated that patients with human immunodeficiency virus infection, those on corticosteroid therapy, patients with chronic obstructive pulmonary diseases, systemic lupus erythematosus, rheumatoid arthritis, or lung cancer are at increased risk for developing infections due to *N. abscessus*.<sup>2,11,12</sup> In our patient, the condition of angiosarcoma and chemotherapy was considered the main predisposing factor for *N. abscessus* infection.

We previously reported that trimethoprim–sulfamethoxazole had good *in vitro* activity against the most common clinical isolates of *Nocardia* species, such as *Nocardia brasiliensis*, but that its activity against other *Nocardia* species varied.<sup>7</sup> We also found that three *N. abscessus* isolates were susceptible to sulfamethoxazole, imipenem, ceftriaxone, and amikacin.<sup>7</sup> By contrast, a study conducted in Spain showed that all six of the clinical isolates of *N. abscessus* analyzed were resistant to imipenem with MIC values  $\geq 32$   $\mu\text{g}/\text{mL}$ .<sup>2</sup> In addition, a study conducted in India reported that two clinical isolates of *N. abscessus* were susceptible to amikacin and tobramycin but that they showed different resistance patterns against azithromycin, clarithromycin, ciprofloxacin, and gatifloxacin.<sup>15</sup> In the present study, we found that *N. abscessus* isolates were susceptible to trimethoprim–sulfamethoxazole and ceftriaxone but resistant to imipenem (MIC  $> 32$   $\mu\text{g}/\text{mL}$ ) that was administered in our patient. Overall, no solid conclusion on the susceptibility profiles of *N. abscessus* can be drawn based on the limited number of *in vitro* studies. The lack of use of trimethoprim–sulfamethoxazole that was active against the *N. abscessus* isolate might partly contribute to the treatment failure of this patient. Further large-scale studies are needed to evaluate the antibiotic resistance pattern of *N. abscessus*.

In conclusion, we have described a fatal case of pneumonia and empyema thoracis caused by trimethoprim–sulfamethoxazole-susceptible, but imipenem-resistant *N. abscessus* in a cancer patient. Sequencing of the 16S rRNA gene is essential for the identification of bacteria in the *Nocardia* genus to the species level.

## References

1. Brown-Elliott BA, Brown JM, Conville PS, Wallace Jr RJ. Clinical and laboratory features of the *Nocardia* spp. based on current molecular taxonomy. *Clin Microbiol Rev* 2006;**19**:259–82.
2. Muñoz J, Mirelis B, Aragón LM, Gutiérrez N, Sánchez F, Español M, et al. Clinical and microbiological features of nocardiosis, 1997–2003. *J Med Microbiol* 2007;**56**:545–50.
3. Minero MV, Marín M, Cercenado E, Rabadán PM, Bouza E, Muñoz P. Nocardiosis at the turn of the century. *Medicine (Baltimore)* 2009;**88**:250–61.
4. Liu WL, Lai CC, Hsiao CH, Hung CC, Huang YT, Liao CH, et al. Clinical and microbiological characteristics of infections caused by various *Nocardia* species in Taiwan: a multicenter study from 1998 to 2010. *Eur J Clin Microbiol Infect Dis* 2011;**30**:1341–7.
5. Menéndez R, Cordero PJ, Santos M, Gobernado M, Marco V. Pulmonary infection with *Nocardia* species: a report of 10 cases and review. *Eur Respir J* 1997;**10**:1542–6.
6. Hui CH, Au VW, Rowland K, Slavotinek JP, Gordon DL. Pulmonary nocardiosis re-visited: experience of 35 patients at diagnosis. *Respir Med* 2003;**97**:709–17.
7. Lai CC, Liu WL, Ko WC, Chen YH, Tan HR, Huang YT, et al. Multicenter study in Taiwan of the *in vitro* activities of nemoxacin, tigecycline, doripenem, and other antimicrobial agents against clinical isolates of various *Nocardia* species. *Antimicrob Agents Chemother* 2011;**55**:2084–91.
8. Yassin AF, Rainey FA, Mendrock U, Brzezinka H, Schaal KP. *Nocardia abscessus* sp. nov. *Int J Syst Evol Microbiol* 2000;**50**:1487–93.
9. Horré R, Schumacher G, Marklein G, Stratmann H, Wardelmann E, Gilges S, et al. Mycetoma due to *Pseudallescheria boydii* and co-isolation of *Nocardia abscessus* in a patient injured in road accident. *Med Mycol* 2002;**40**:525–7.
10. Welling N, Pietzcker T, Kern WV, Essig A, Marre R. Expanded spectrum of *Nocardia* species causing clinical nocardiosis detected by molecular methods. *Int J Med Microbiol* 2002;**292**:277–82.
11. Kageyama A, Yazawa K, Kudo T, Taniguchi H, Nishimura K, Mikami Y. First isolates of *Nocardia abscessus* from humans and soil in Japan. *Nippon Ishinkin Gakkai Zasshi* 2004;**45**:17–21.
12. Diego C, Ambrosioni JC, Abel G, Fernando B, Tomas O, Ricardo N, et al. Disseminated nocardiosis caused by *Nocardia abscessus* in an HIV-infected patient: first reported case. *AIDS* 2005;**19**:1330–1.
13. Wauters G, Avesani V, Charlier J, Janssens M, Vaneechoutte M, Delmee M. Distribution of *Nocardia* species in clinical samples and their routine rapid identification in the laboratory. *J Clin Microbiol* 2005;**43**:2624–8.
14. Marchandin H, Eden A, Jean-Pierre H, Reynes J, Jumas-Bilak E, Boiron P, et al. Molecular diagnosis of culture-negative cerebral nocardiosis due to *Nocardia abscessus*. *Diagn Microbiol Infect Dis* 2006;**55**:237–40.
15. Reddy AK, Garq P, Kaur I. Speciation and susceptibility of *Nocardia* isolated from ocular infections. *Clin Microbiol Infect* 2010;**16**:1168–71.
16. Larruskain J, Idigoras P, Marimón JM, Pérez-Trallero E. Susceptibility of 186 *Nocardia* sp. Isolates to 20 antimicrobial agents. *Antimicrob Agents Chemother* 2011;**55**:2995–8.