

Kikuchi-Fujimoto disease in children: clinical features and disease course

Tai-Ju Wang¹, Yao-Hsu Yang², Yu-Tsan Lin², Bor-Luen Chiang²

¹Department of Pediatrics, Cathay General Hospital, Taipei; and ²Department of Pediatrics, National Taiwan University Hospital, Taipei, Taiwan, ROC

Received: August 30, 2003 Revised: October 23, 2003 Accepted: November 9, 2003

Kikuchi-Fujimoto disease (KFD) is a rare cause of cervical lymphadenitis which mostly affects Asian women but is sometimes observed in the pediatric population. This study analyzed the clinical manifestations and disease course in children with KFD. Retrospective chart review and telephone interview were used to collect data for 13 children (8 boys and 5 girls) with a diagnosis of KFD from January 1988 to January 2003. Involvement of the posterior cervical lymph nodes was found in 12 patients, leukopenia in 9, and all patients had C-reactive protein less than 5 mg/dL. A high antinuclear antibody titer was associated with a more protracted and complicated course. Five of the 13 patients had new symptoms compatible with an autoimmune process during follow-up, with neurological symptoms the most common. In conclusion, the risk of evolution into an autoimmune syndrome in pediatric KFD patients is high, and careful long-term observation is mandatory.

Key words: Histiocytic necrotizing lymphadenitis, Kikuchi-Fujimoto disease, prognosis, retrospective studies

Kikuchi-Fujimoto disease (KFD) is a clinicopathological condition characterized by subacute necrotizing lymphadenitis, most commonly involving the cervical lymph nodes. It typically affects young Asian women aged around 30 years. KFD was first described by Kikuchi [1] and Fujimoto et al [2] independently in 1972 as a cervical lymphadenopathy, and it has been recently shown to have a wide variety of clinical presentations, including aseptic meningitis or encephalitis [3-5], polyarthritis [6], myalgia, hepatosplenomegaly and skin rash. KFD is sometimes misdiagnosed as systemic lupus erythematosus (SLE) because of the overlapping clinical presentation [7-10]. As first described by Gleeson et al in 1985 [11], the pathological features of KFD include lymph node necrosis with karyorrhexis surrounded by histiocytes, without granuloma formation, and absence of neutrophilic or plasma cell infiltration. Special stains for acid-fast bacilli, spirochetes, and fungus should be negative [3].

Although it is a rare disease in the pediatric population, KFD should be considered in the differential diagnosis of many infections, collagen diseases or even malignancy. Furthermore, owing to the wide variability of clinical manifestations, a primary care physician

should always keep in mind the possibility of KFD during follow-up of patients. This study analyzed the clinical characteristics and disease course in children with KFD treated at a medical center.

Materials and Methods

Thirteen children with a diagnosis of KFD who were treated at National Taiwan University Hospital between January 1988 and January 2003 were included in the study. There were 24 episodes of cervical lymphadenopathy. Medical charts were reviewed and telephone interviews were conducted to collect data and to determine whether there were newly developed symptoms and signs and if patients had received medication from other sources.

All patients in this study were under 19 years old at the time of diagnosis. Most received lymph node excisional biopsy, while 1 patient had fine needle aspiration.

Results

Demographic characteristics

Among the 13 patients, 5 (38%) were girls and 8 (62%) were boys. The age at presentation of lymphadenopathy ranged from 6 years and 3 months to 18 years and 1 month (mean, 10 years and 1 month). The month at

Corresponding author: Dr. Bor-Luen Chiang, Department of Pediatrics, National Taiwan University Hospital, No 7, Chung-Shan South Road, Taipei, Taiwan, ROC.
E-mail: gicmbor@ha.mc.ntu.edu.tw

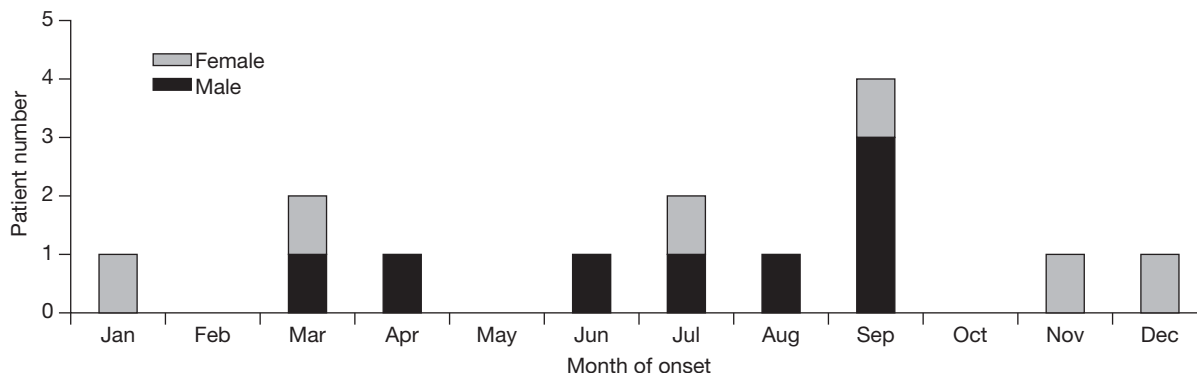


Fig. 1. Distribution of gender and month of onset of lymphadenopathy in 13 patients with Kikuchi-Fujimoto disease.

the time of initial lymphadenopathy onset is shown in Fig. 1. Although there were 4 cases in September, further interpretation was difficult owing to the small case number in this study.

Clinical presentation

The demographic features of the 13 patients are summarized in Table 1. Twelve of the 13 patients had lymphadenopathy as the initial presentation, while 1 had bilateral knee arthritis 3 months preceding the onset of lymphadenopathy. Multiple lymph nodes were invariably involved, and the posterior cervical lymph nodes were involved in 92% (12/13) of the patients. Concurrent extracervical lymphadenopathy was noted in only 1 of the patients. This patient still underwent lymph node biopsy on his cervical lymph nodes. The largest lymph node in each patient ranged from 1 cm × 1 cm to as large as 8 cm × 8 cm. All patients had tender lymphadenopathy, and the lymph nodes were fixed in 5 patients.

Fever accompanying the lymphadenopathy was noted in 12 patients, and this accounted for only half of the total 24 lymphadenopathy episodes during follow-up. One patient had prolonged fever for 3 weeks prior to the development of lymphadenopathy. The fever in the 12 patients often spiked to more than 40°C. Defervescence occurred either before (8 cases) or after biopsy (4 cases).

Associated symptoms and signs, defined as physical discomfort occurring within 1 week before or after the occurrence of lymphadenopathy, are summarized in Table 2. One of the 2 patients who experienced coughing had positive mycoplasma immunoglobulin M (IgM).

Laboratory findings

At presentation, 67% of patients had leukopenia, defined as a total white blood cell (WBC) count not more than 4000/μL. The mean WBC count was 4089/μL, ranging from 1030 to 12,180/μL. Only 1 patient had leukocytosis (>10,000/μL) accompanied by coughing at presentation. Platelet counts were within normal

Table 1. Demographic features of 13 children with Kikuchi-Fujimoto disease (only the initial presentation is listed)

Patient no.	Gender	Age	Fever	Lymphadenopathy characteristics	Max. size (cm)	Tender	ANA	CRP (mg/dL)
1	Male	6 y, 2 m	+	L post-cervical; bil supraclavicular	1.0 × 1.0	+	1:40	0.62
2	Female	7 y, 8 m	+	L post-cervical; bil carotid	3.0 × 4.0	+	NP	2.42
3	Female	18 y	+	L post-cervical	1.5 × 1.0	ND	NP	0.41
4	Male	11 y, 5 m	+	L, ND	3.0 × 2.0	+	1:40	ND
5	Male	10 y, 9 m	+	L, R post-cervical	8.0 × 8.0	+	NP	4.80
6	Male	6 y, 4 m	+	R post-cervical & submandibular	3.0 × 4.0	+	NP	2.28
7	Female	11 y, 5 m	+	L, R post-cervical	6.0 × 4.0	+	NP	0.39
8	Male	9 y, 4 m	+	L, R post cervical; L submandibular	2.0 × 3.0	+	1:320	0.36
9	Male	6 y, 8 m	+	L post-cervical; small inguinal nodes	2.0 × 2.0	-	1:40	<0.60
10	Male	9 y, 1 m	-	L, ND	ND	ND	NP	NP
11	Female	12 y, 5 m	+	R post-cervical and supraclavicular	3.0 × 1.5	ND	NP	NP
12	Male	9 y, 2 m	+	L post-cervical	2.0 × 3.0	+	NP	NP
13	Female	11 y, 11 m	+	L post-cervical	1.5 × 2.0	+	1:40	0.34

Abbreviations: ANA = antinuclear antibody; CRP = C-reactive protein; WBC = white blood cells; Seg = segmented WBC; y = years; m = month(s); described in record; GOT = glutamate oxaloacetate transaminase; GPT = glutamate pyruvate transaminase; HHV-6 = human herpes virus type 6;

Table 2. Summary of the accompanying symptoms and signs in 13 children with Kikuchi-Fujimoto disease

Symptoms and signs	No. of patients (%)
Skin rash	4 (31)
Headache	4 (31)
Elevated GPT	4 (31)
Nausea and/or vomiting	3 (23)
Oral ulcer	3 (23)
Hepatomegaly	3 (23)
Arthralgia/arthritis	2 (15)
Cough	2 (15)
Vertigo	2 (15)
Chills	2 (15)
Hair loss	1 (8)
Generalized malaise	1 (8)
Photosensitivity	1 (8)
Lethargy	1 (8)
Body weight loss	1 (8)

Abbreviation: GPT = glutamate pyruvate transaminase

limits in the majority of cases (92%, details not shown), ranging from 139,000 to 423,000 (average, 239,000).

C-reactive protein (CRP) levels were universally low and were less than 5 mg/dL in all patients. Amino-transferase was checked only in a few patients. Though some patients had mildly elevated levels, 1 patient had an aspartate transaminase level at 1130 U/L and alanine transferase at 800 U/L. Paired serum data in that patient suggested Epstein-Barr virus (EBV) reactivation. No jaundice was observed clinically, and bilirubin levels were not elevated in the few cases checked.

The antinuclear antibody (ANA) titers checked during the initial visit revealed elevation in only 1 patient with 1:640 (nucleolar pattern). The titers in

the remaining patients were either 1:40 (-) or 1:40 (+). Follow-up ANA titers revealed increased titers in 3 patients, 1 up to 1:160 and 2 up to 1:320 (speckled pattern). All 3 of these patients had a more complicated clinical course. C3 and C4 levels were mostly within normal limits, ranging from 67.1 to 129 mg/dL and 15.5 to 40.8 mg/dL, respectively.

Throat swab for viral isolation and serology tests for human herpes virus type 6 (HHV-6), parainfluenza virus, and EBV were performed. One patient had positive mycoplasma IgM, and another had positive HHV-6 IgM. Patient 6 had a very high EBV-VCA (viral capsid antigen) IgG titer (1:5120), although the paired serum did not suggest a recent infection. All virus cultures were negative.

Clinical course and treatment

Eight of the 13 patients had a monophasic course, while the rest had recurrences of lymphadenopathy with or without fever during follow-up. The period of follow-up ranged from 5 months to 15 years and 1 month (mean, 5 years and 8 months). Five patients had complicated courses which are summarized as follows.

Patient 2 was a girl aged 7 years and 8 months at diagnosis. Persistent left knee arthritis developed 1 month later, followed by polymyalgia. Easy bruising and hair loss was noted and the ANA titer was 1:160 (speckled pattern). No new discomfort was observed afterwards.

Patient 5 was found to have a transient generalized erythematous skin rash 2 weeks after the initial febrile lymphadenopathy. Aphthous oral ulcers were found as well. He was symptom-free afterwards.

WBC (μ L)	Seg (%)	Other positive laboratory findings	Steroid	Recurrence	Comments
12180	7	Mycoplasma IgM (+)	-	-	
3330	47	EBV-VCA IgG titer, 1:5120	+	+	
2330	39	Band form 9%	ND	+	Preceding idiopathic pancreatitis
4220	57	Nil	-	-	
1030	67	Nil	-	+	
4700	50	GOT/GPT=1130/800 (U/L)	+	+	Serology: EBV reactivation
3700	50	HHV-6 IgM (+)	ND	+	Diagnosed to have JRA
3150	54	GOT/GPT=112/95 (U/L)	+	-	
4000	33	GOT/GPT=169/120 (U/L)	ND	+	
NP	NP	Nil	ND	-	
NP	NP	Nil	+	-	
3450	45	GOT= 60 (U/L)	ND	-	
2650	65	Nil	-	+	

IgM = immunoglobulin M; NP = not performed; EBV-VCA = Epstein-Barr virus-viral capsid antigen; IgG = immunoglobulin G; ND = not JRA = juvenile rheumatoid arthritis

Patient 6 suffered from febrile headache and nausea 5 years after diagnosis, followed by central vertigo, vertical nystagmus, and ataxia. Magnetic resonance imaging revealed bilateral medulla oblongata lesions. ANA was 1:640 (nucleolar pattern). He received intravenous immunoglobulin, but his symptoms did not improve until dexamethasone was administered. Concurrent mild proteinuria without hematuria was noted, and SLE was diagnosed and was controlled with azathioprine and hydroxychloroquine. At 7 years after the diagnosis of KFD, febrile cervical lymphadenopathy recurred, while complement and urinalysis were normal and ANA was negative.

Patient 7 presented with bilateral knee arthritis at the age of 11 years. Three months later, fever with cervical lymphadenopathy occurred and KFD was diagnosed. HHV-6 IgM was positive. The arthritis persisted, and juvenile rheumatoid arthritis was diagnosed. At 15 months, she experienced migraine-like headaches with vertigo and tinnitus. Electroencephalography identified a right central partial seizure. Persistent low back pain developed, with oral ulcer and alopecia. ANA and complements were normal. Intermittent polyarthralgia, oral ulcers and photosensitivity, and ANA titer increase to 1:320 (speckled pattern) were noted during follow-up.

Patient 13 began to suffer from tinnitus, vertigo and nystagmus at 1 month after the initial diagnosis of KFD, followed by recurrence of febrile lymphadenopathy with polyarthralgia, vertigo, malaise and later malar rash. Fever subsided after the use of corticosteroids. Bone marrow examination revealed hypocellularity. Photosensitivity, malar rash and vertigo recurred 6 months after diagnosis, followed by cervical lymphadenopathy and polyarthralgia. Intention tremors and intermittent left hemiparesis, slurred speech, petechiae and purpura were also noted. Aseptic meningoencephalitis occurred at the 19th and 24th month after diagnosis. The ANA titer increased to 1:160 (+) (homogeneous pattern). Thereafter, she continued to suffer from intermittent leg weakness. The chronic relapsing neurological symptoms were regarded as an autoimmune phenomenon related to KFD.

Discussion

In this study, 38% (5/13) of children with KFD were girls and 62% (8/13) were boys. This ratio was different from most of the previous studies conducted with adult patients, in which the female-to-male ratio ranged from

2:1 to 4:1, although a series reported by Kuo found a ratio of 1.1:1 [12]. The age at disease onset was not different between boys and girls. Four out of 13 patients had disease onset in September.

Infectious causes of KFD have long been sought for with little definitive results. Pathogens reported in association with KFD include *Yersinia enterocolitica* [13], *Toxoplasma gondii* [3,14], cytomegalovirus, parvovirus B19, type 1 human T-cell lymphotropic virus (HTLV-1), HHV-6 and -8, EBV, parainfluenza and varicella-zoster virus. A recent study by Chiu et al suggested that EBV plays an important role in the evolution of KFD [15].

The histological change in KFD has been classified into 3 stages: an early proliferative stage, an intermediate phagocytic stage, and a full-blown post-necrotic or xanthomatous stage [12,16]. During the proliferative stage, CD116 and CD11c positive histiocytes predominate and are accompanied by numerous atypical lymphocytes, which are primarily CD4+ T helper cells. In contrast, CD8+ suppressor T lymphocytes are the most predominant cells in the post-necrotic stage [3,17,18].

A previous study reported that the lymphadenopathy was isolated in 1 location in 83% of cases, though multiple chains of lymph nodes may have been involved [19]. In this study, the size of lymphadenopathy was not correlated with a more protracted course. A strong tendency to involve the posterior cervical lymph nodes was noted in our series. Some previous reports noted a rate of posterior cervical triangle involvement from 65 to 70% [20-22].

Tender lymphadenopathy was the most common (70%) presenting sign in our patients. This is in contrast to previous reports in which lymph node tenderness was minimal to none [3,12]. Though usually less than 2 cm in most series, many of our patients had larger lymphadenopathy and 1 patient presented with swelling measuring 8 cm × 8 cm. In this patient, ring enhancement was noted on computed tomography (CT). Extracervical lymphadenopathy was found in only 1 patient in this study.

In this series, fever often subsided after biopsy, which is in agreement with other reports [3,12]. The elimination of an inflammatory focus may explain this phenomenon. Nonetheless, fever subsided spontaneously in some patients, and others had spontaneous resolution of the lymphadenopathy.

The proliferative stage of KFD can sometimes be confused with malignant lymphoma [3,20]. Thirty percent of the 108 lymph nodes reviewed by Dorfman

and Berry were initially misdiagnosed as malignant lymphoma [3]. An experienced pathologist familiar with both diseases is of the utmost importance to avoid unnecessary interventions, including chemotherapy.

The anterior triangle lymph nodes are more frequently involved during viral infections. Involvement of the axillary and supraclavicular chains has been reported to occur in less than 15% of cases [13]. This could possibly serve as a clue to differentiate KFD from simple viral infection-related lymphadenopathy, both of which often present with leukopenia.

Besides viruses, certain bacterial infections such as tuberculosis, cat scratch disease and tularemia should also be considered in the differential diagnosis of KFD. With the increasing prevalence of human immunodeficiency virus infection worldwide, atypical pathogens should be considered according to individual clinical manifestations.

Extranodal involvement is rare in KFD but has been documented in skin, myocardium, and bone marrow [21,23-25]. In our study, cutaneous involvement was observed in 31% of patients (4/13), and was described as maculopapular or morbilliform, or photosensitive. No pathognomonic pattern has been reported. Although cutaneous involvement in KFD was associated with a more severe course in certain series [24], no such association was found in our patients. The differential diagnosis included erythema multiforme, SLE, discoid lupus, and drug eruption.

Although laboratory tests did not establish a diagnosis of KFD, it is sometimes useful to rule out certain differentials. Leukopenia was frequently observed (69%) in our study. This is in contrast to a previous study in which 80.8% of patients had normal WBC counts [21]. In some series, granulocytopenia was more prominent and was noted in as many as 50% of patients [3,12,21]. In contrast, our patients had normal differential counts, and the decrease in the WBC number was not secondary to the decrease of a specific subset. Furthermore, CRP was low in most patients, which was also different from observations in a previous study [3].

Although image studies cannot be used to diagnose KFD, a chest film is still mandatory since tuberculosis and lymphoma should be ruled out. CT should be performed when lymphoma or abscess is suspected.

The association with KFD and SLE is well established [7-10]. The time from the initial diagnosis of KFD to SLE ranged from 10 months to 3 years [12,26]. KFD has been associated with mixed connective

tissue disease and Still's disease in rare cases [27]. It has been suggested that apoptosis plays an important role in the pathogenesis of KFD [28,29]. The autoimmune symptoms and hypogammaglobulinemia in patient 5 of this series could have been the result of a defective apoptosis process. One of our patients had idiopathic pancreatitis 2 months prior to the onset of lymphadenopathy. Whether it was a presentation of an autoimmune phenomenon is not known.

Most cases with KFD have spontaneous resolution within several weeks to 6 months with a recurrence rate of 3.3% [12]. Patients 3 and 5 in this series had febrile headaches during follow-up. Vasculitis syndrome could also present with similar symptoms, although there was no concurrent involvement of any other organ systems in these patients, and the inflammatory markers were not elevated. In a study of 41 patients by Sato et al, 4 (9.8%) developed aseptic meningitis, with male patients having higher susceptibility [4].

In summary, in this long-term follow-up study of children with a diagnosis of KFD, a significant percentage (5/13) of patients had new symptoms months to years later. Their conditions were highly variable, but all could be explained by the presence of an autoimmune process. The risk of evolution into an autoimmune syndrome in pediatric KFD patients seems to be high, and a long-term follow-up period is mandatory.

References

1. Kikuchi M. Lymphadenitis showing focal reticulum cell hyperplasia with nuclear debris and phagocytes. *Acta Haematol Jpn* 1972;35:379-80.
2. Fujimoto Y, Kojima Y, Yamaguchi K. Cervical subacute necrotizing lymphadenitis. *Naika* 1972;30:920-7.
3. Dorfman RF, Berry GJ. Lymphadenitis: an analysis of 108 cases with emphasis on differential diagnosis. *Semin Diagn Pathol* 1988;5:329-45.
4. Sato Y, Kuno H, Oizumi K. Histiocytic necrotizing lymphadenitis (Kikuchi's disease) with aseptic meningitis. *J Neurol Sci* 1999;163:187-91.
5. Nishiyama K, Sakai K, Takeda K. Subacute necrotizing lymphadenitis associated with encephalitis, successfully treated by vidarabine. A case report. *Neurol Med (Tokyo)* 1993;39:428-30.
6. Graham LE. Kikuchi-Fujimoto disease and peripheral arthritis: a first! *Ann Rheum Dis* 2002;61:475.
7. Imamura M, Ueno H, Matsuura A, Kamiya H, Suzuki T, Kikuchi K, et al. An ultrastructural study of subacute necrotizing lymphadenitis. *Am J Pathol* 1982;107:292-9.
8. Sire S, Djossou F, Deminiere C, Constans J, Ragnaud JM,

- Aubertin J. Kikuchi-Fujimoto necrotizing lymphadenitis: apropos of 2 cases and review of the literature. *Rev Med Interne* 1996;17:842-5.
9. Chua SH, Giam YC, Sim CS. Systemic lupus erythematosus with erythema multiform-like lesions and histiocytic necrotizing lymphadenitis—a case report. *Ann Acad Med Singapore* 1996; 25:599-661.
 10. Hoffmann A, Kirn E, Kuerten A. Active human herpesvirus 6 (HHV-6) infection associated Kikuchi-Fujimoto disease and systemic lupus erythematosus (SLE). *In Vivo* 1991;5:265-9.
 11. Gleeson MJ, Siodlak MZ, Barbatis C, Salama NY. Kikuchi's—a new cause of cervical lymphadenopathy. *J Laryngol Otol* 1985;99:935-9.
 12. Kuo TT. Kikuchi's disease (histiocytic necrotizing lymphadenitis). A clinicopathologic study of 79 cases with an analysis of histologic subtypes, immunohistology, and DNA ploidy. *Am J Surg Pathol* 1995;19:798-809.
 13. Feller AC, Lennert K, Stein H, Bruhn HD, Wuthe HH. Immunohistology and aetiology of histiocytic necrotizing lymphadenitis. Report of three instructive cases. *Histopathol* 1983;7:825-39.
 14. Kikuchi M, Yoshizumi T, Nakamura H. Necrotizing lymphadenitis: Possible acute toxoplasmic infection. *Virchows Arch A Pathol Anat Histol* 1977;376:247-53.
 15. Chiu CF, Chow KC, Lin TY, Tsai MH, Shih CM, Chen LM. Virus infection in patients with histiocytic necrotizing lymphadenitis in Taiwan: Detection of Epstein-Barr Virus, type 1 human T-cell lymphotropic virus, and parvovirus B19. *Am J Clin Pathol* 2000;113:774-81.
 16. Kikuchi M. Histiocytic necrotizing lymphadenitis (Kikuchi-Fujimoto disease) in Japan. *Am J Surg Pathol* 1991;15:197-8.
 17. Ali MH, Horton LWL. Necrotizing lymphadenitis without granulocytic infiltration (Kikuchi's disease). *J Clin Pathol* 1985; 38:1252-7.
 18. Ohshima K, Kikuchi M, Suniyoshi Y, Masuda Y, Mohtai H, Eguchi F, et al. Proliferating cells in histiocytic necrotizing lymphadenitis. *Virchows Arch B Cell Incl Molo Pathol* 1991; 61:97-100.
 19. Garcia CE, Girdhar-Gopal HV, Dorfman DM. Kikuchi-Fujimoto disease of the neck: update. *Ann Otol Rhinol Laryngol* 1993;102(1 Pt 1):11-5.
 20. Chamulak GA, Brynes RK, Nathwani BN. Kikuchi-Fujimoto disease mimicking malignant lymphoma. *Am J Surg Pathol* 1990;14:514-23.
 21. Turner RR, Martin J, Dorfman RF. Necrotizing lymphadenitis. A study of 30 cases. *Am J Surg Pathol* 1983;7:115-23.
 22. Hsueh EJ, Ko WS, Hwang WS, Yam LT. Fine-needle aspiration of histiocytic necrotizing lymphadenitis (Kikuchi's disease). *Diagn Cytopathol* 1993;9:448-52.
 23. Chan JK, Wong KC, Ng CS. A fatal case of multicentric Kikuchi's histiocytic necrotizing lymphadenitis. *Cancer* 1989; 63:1856-62.
 24. Sushiyomi Y, Kikuchi M, Obshima K, Masuda Y, Takeshita M, Okamura T. A case of histiocytic necrotizing lymphadenitis with bone marrow and skin involvement. *Virchows Arch A Pathol Anat* 1992;420:275-9.
 25. Seno A, Torigoe R, Shimoe K, Tada J, Arata J, Suwaki M. Kikuchi's disease (histiocytic necrotizing lymphadenitis) with cutaneous involvement. *J Am Acad Dermatol* 1994;30:504-6.
 26. Vila LM, Mayor AM, Silvestrini IE. Therapeutic response and long-term follow-up in a systemic lupus erythematosus patient presenting with Kikuchi's disease. *Lupus* 2001;10:126-8.
 27. Gourley I, Bell AL, Biggart D. Kikuchi's disease as a presenting feature of mixed connective tissue disease. *Clin Rheumatol* 1995;14:104-7.
 28. Fergar RE, Furth EE, Wasik MA, Gluckman SJ, Salhany KE. Histiocytic necrotizing lymphadenitis (Kikuchi's disease): *in situ* end-labeling, immunohistochemical, and serologic evidence supporting cytotoxic lymphocyte-mediated apoptotic cell death. *Mod Pathol* 1997;10:231-41.
 29. Ohshima K, Shimazaki K, Kume K, Suzumiya J, Kanda M, Kikuchi M. Perforin and fas pathways of cytotoxic T-cells in histiocytic necrotizing lymphadenitis. *Histopathology* 1998;33: 471-8.