

Henoch-Schönlein purpura with hemorrhagic bullae in children: report of two cases

Po-Mai Liu¹, Chin-Nam Bong², Hsin-Hsu Chen³, Yi-Chuan Huang³, Chao-Cheng Huang⁴,
Kuender D. Yang³, Chih-Lu Wang³

¹Department of Pediatrics, E-Da Hospital, Kaohsiung; ²Department of Pediatrics, Pingtung Christian Hospital, Pingtung; and Departments of ³Pediatrics and ⁴Pathology, Chang Gung Children's Hospital, Kaohsiung, Taiwan, ROC

Received: January 19, 2004 Revised: March 1, 2004 Accepted: June 6, 2004

Henoch-Schönlein purpura (HSP) is the most common form of acute vasculitis primarily affecting children. Clinical features include skin rashes, arthritis, abdominal pain and nephritis. Skin biopsy on immunofluorescence often reveals granular depositions of immunoglobulin A (IgA) and C3 within the walls of the dermal vessels as well as in the connective tissue of the upper dermis. The diversity of skin rashes produces confusion in diagnosis of HSP, especially in the presence of bullous lesions. Bullous lesions are very rare in children with HSP, whereas they often appear in adults with HSP. We report 2 cases of HSP in whom hemorrhagic bullae manifested predominantly. In our report, the skin biopsies of both patients revealed typical leukocytoclastic vasculitis without IgA and complement depositions on direct immunofluorescence studies. Dramatic improvement of clinical symptoms and signs was observed within a few days after corticosteroids were administered. There was neither recurrence nor nephritis in these 2 patients.

Key words: Hemorrhagic bullae, Henoch-Schoenlein purpura, leukocytoclastic vasculitis, vesiculobullous skin diseases

Henoch-Schönlein purpura (HSP) is the most common form of acute vasculitis primarily affecting children. Clinical features include skin rashes, arthritis, abdominal pain and nephritis [1]. The dermatographic manifestations present classically as urticarial wheals, erythematous maculopapules, petechiae, purpura, or subcutaneous edema, which characteristically involve the lower extremities and buttocks, but may also distribute over the upper extremities, face and trunk [2]. The diversity of skin rashes produces confusion in the diagnosis of HSP, especially in the presence of bullous lesions. To our knowledge, bullous lesions are very rare in children with HSP. We therefore report 2 cases of HSP in which hemorrhagic bullae manifested predominantly.

Case Report

Patient 1

A previously healthy 7-year-old girl suffered from an episode of respiratory tract infection combined with

fever. Skin rashes and arthralgia developed 2 days later. The rashes presented as palpable purpuric lesions initially, which were distributed on the buttocks and lower extremities. Bullae developed within 3 days. The patient was then admitted to our hospital. On examination, the patient had diffuse purpura over her buttocks and lower extremities. Multiple hemorrhagic bullae in various sizes were located on the base of the pupura (Fig. 1). They ranged in size from 2 to 10 mm in diameter.

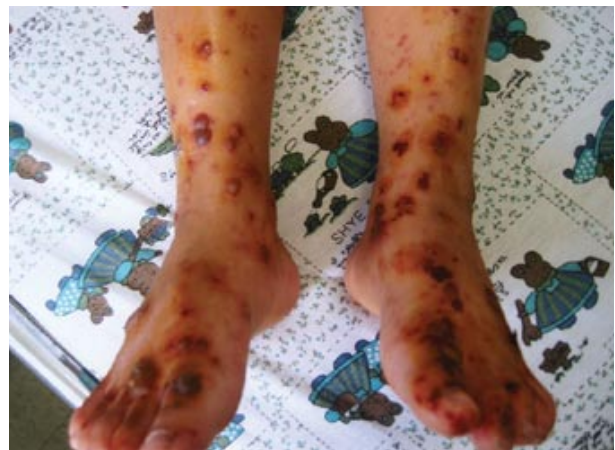

Fig. 1. Hemorrhagic bullae on bilateral feet

Corresponding author: Dr. Chih-Lu Wang, Department of Pediatrics, Chang Gung Children's Hospital, 123 Ta-Pei Road, Niao-sung Hsiang, Kaohsiung, Taiwan 833, ROC.
E-mail: drlulu@adm.cgmh.org.tw

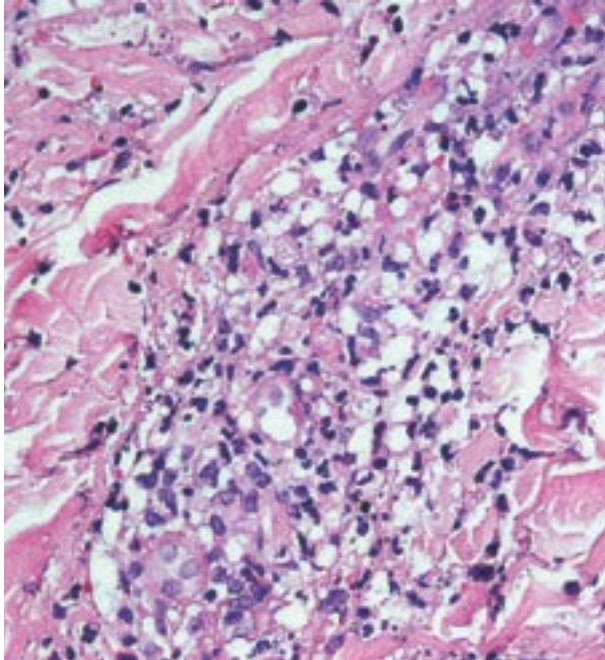


Fig. 2. Skin biopsy specimen shows perivascular neutrophilic infiltration with nuclear dust in the dermis (hematoxylin and eosin stain, $\times 200$)

Laboratory studies showed a white blood cell count of 10,400/ μL with 65% granulocytes and 28% lymphocytes, hemoglobin 12.8 g/dL, platelet count 566,000/ μL , and C-reactive protein (CRP) 28.1 mg/L (normal, <5 mg/L). Microscopic analysis of urine was normal. Serum immunoglobulin G (IgG), IgM, and IgE were normal for her age, and IgA (586 mg%) was noted as elevated (normal, 75-375 mg%). Occult blood was negative in a stool sample. Throat swab for viral culture and serologic titers for herpes simplex virus both produced negative results. A skin biopsy specimen showed subepidermal blister with leukocytoclastic vasculitis (Fig. 2). However, neither IgA nor C3 deposition was found in immunofluorescence studies.

This patient received oxacillin initially for suspicion of cellulitis and then hydrocortisone was administered in a dose of 20 mg/kg/day under the impression of HSP. The hemorrhagic bullae and arthralgia resolved within 1 week without any other sequelae. No recurrence was found in the following 6 months despite some episodes of pharyngitis occurring during this period.

Patient 2

A 6-year-old boy was admitted to our hospital with a 1-day history of limping gait owing to unilateral arthralgia over the left knee. In addition, disseminated polymorphic

rashes on his buttocks and lower extremities with mild edema were found. He had not been receiving any medication and had not been exposed to any animals. On examination, scattered tiny macules and purpura with blisters and central necrosis was found over the lower extremities and buttocks. Neurological signs on physical examination were negative. During hospitalization, abdominal pain was also found, with several episodes of non-bilious vomiting.

Laboratory data revealed a white blood cell count of 13400/ μL with 72% granulocytes, 21% lymphocytes, hemoglobin 10.8 g/dL, platelets 373,000/ μL , and CRP 15.3 mg/L (normal, <5 mg/L). C3, C4 and albumin were within a normal range, and antinuclear antibody (ANA) was found to be negative, as was urinalysis. Serum IgG, IgM, and IgE were normal for his age. IgA (371 mg%) was also within a normal range (normal, 75-375 mg%). Throat swab for viral culture and serologic titers for cytomegalovirus and Epstein-Barr virus revealed negative findings. A skin biopsy specimen showed typical leukocytoclastic vasculitis. Neither IgA nor C3 deposition was found in immunofluorescence studies.

The patient received ceftazidime initially under the impression of meningococemia. The treatment was switched to hydrocortisone when a diagnosis of HSP was made. Arthralgia and abdominal pain resolved promptly after steroid therapy, and the skin rash faded within the next several days. The necrotic lesions healed with mild pigmentation and scar formation. No recurrence was found in the following 6 months.

Discussion

HSP is characterized by palpable purpura over the legs and buttocks and may also distribute to the upper extremities and face [2]. Other dominant clinical manifestations include arthritis, abdominal pain, gastrointestinal bleeding and nephritis. Criteria for identifying HSP and distinguishing HSP from other forms of vasculitis were proposed in 1990, of which at least 2 of the following are required for diagnosis of HSP: (1) palpable purpura; (2) age ≤ 20 years at disease onset; (3) bowel angina; and (4) granulocytes in the walls of the arterioles or venules on biopsy [3].

Manifestations of the patients in this report fulfilled the typical features of HSP, including arthritis and purpura, despite rashes presenting as pupura with hemorrhagic bullae rather than simple purpura. Both of their onsets occurred at less than 20 years old, which matches the criteria for HSP. The presence of

leukocytoclastic vasculitis in the skin biopsy specimens from our patients lends further support to the diagnosis of HSP [4].

HSP is the most common form of acute vasculitis affecting children, and the majority of patients exhibit typical pupura. The diagnosis is based primarily on the clinical manifestations, and skin biopsy is not necessary to establish a diagnosis of HSP in such patients. However, there is a substantial number of patients with variable cutaneous manifestations for whom skin biopsies become indispensable for diagnosis. Polymorphism of skin rashes and the variable timing of the development of purpura increase the difficulty and confusion in diagnosis. In most patients, purpura follows abdominal pain and arthritis within 1 week. Occasionally, cutaneous purpura briefly precedes or occurs simultaneously with them. However, nephritis virtually never precedes other signs and symptoms in children, a feature that helps to distinguish HSP from other glomerulonephritis [1]. In adults, disease onset is characterized by a higher frequency of nephritis other than abdominal pain [5]. The skin is a major target organ in HSP, and palpable purpura is the hallmark of HSP. Purpura is concentrated on the buttocks and lower extremities, and it may be preceded by a maculopapular or urticarial rash. The purpuric areas evolve from red to purple, becoming rust-colored with a brownish hue, and eventually fade [2]. There are other variant cutaneous manifestations of HSP including petechiae and subcutaneous edema.

The 2 patients in our report presented typical purpura of HSP over the buttocks and legs initially, but hemorrhagic bullae developed on the base of the purpura or around them a few days later. Skin biopsies were then performed to confirm the diagnosis of HSP. The biopsy specimens of our 2 patients revealed similar pictures in which leukocytoclastic vasculitis was found without immunoglobulin deposition in immunofluorescence studies. HSP is a leukocytoclastic vasculitis that affects small vessels (arterioles and venules). The characteristic histological finding is perivascular accumulation of polymorphonuclear leukocytes involving papillary and dermal vessels. Extravasation of erythrocytes also occurs in purpuric lesions, while in late stages mononuclear cells may predominate [6]. In addition, skin biopsies on immunofluorescence often reveal granular depositions of IgA and C3 within the walls of the dermal vessels as well as in the connective tissue of the upper dermis. However, among 14 patients of HSP in Giangiacomo

and Tsai's series, 1 case (7%) had no deposition of IgA and C3 on direct immunofluorescence studies [4]. This male patient presented with skin rashes, arthritis and hematuria with normal renal function.

In another series conducted by Nussinovitch et al, 5 cases of HSP (71%) among the youngest subgroup, in which all patients were younger than 1 year old, revealed negative findings on direct immunofluorescence studies. All of the patients in this subgroup had no systemic involvement [7]. The presence of deposition of IgA and C3 on direct immunofluorescence is nonspecific, but seems to be less frequent in young children. However, the presence of deposition of IgA and C3 would lead the diagnosis toward HSP, although it is not obligatory on diagnosis for HSP. On the other hand, when this result is combined with selected clinical data, it might improve the diagnostic accuracy for HSP [8]. In another series conducted by Tancrede-Bohin et al, there was no statistically significant correlation between IgA glomerulonephritis and bullous cutaneous lesions or the severity of skin biopsies [9]. In this study, all patients were enrolled by modified criteria, including positive IgA depositions on direct immunofluorescence studies of skin biopsies. The clinical significance in the presence or absence of this finding could not be evaluated in this study. Furthermore, HSP is associated with a variety of abnormalities involving IgA, including increased serum IgA concentrations and IgA-containing circulating immune complexes [10].

Further studies are needed to investigate the role of IgA in clinical symptoms and signs of HSP. Moreover, nephritis is a manifestation of HSP that may become chronic. Other findings, such as inflammatory syndrome, could be considered as predicting factors for the development of nephritis [9]. The reason for the absence of the deposition of IgA or C3 on direct immunofluorescence studies in the 2 patients of our report is unclear. Maybe the amount of IgA or C3 in these 2 patients was under the detectable level on direct immunofluorescence studies of skin biopsy specimens. Furthermore, there was neither recurrence nor nephritis found in the 2 patients. This smooth and self-limited clinical course might be attributable to the low levels of IgA and C3, which were almost undetectable. Similar cases should be collected to clarify this issue.

Bullous lesions or hemorrhagic bullae are very rare in children with HSP, whereas they often appear in adults with HSP. Saulsbury in 1998 reported 2 other pediatric

cases of HSP with hemorrhagic bullae that had neither severe nor prolonged clinical courses [11]. The precise incidence of this manifestation in children with HSP is still unknown. However, only about less than 2% of children with HSP have been found to have bullous lesions in previous reports [12]. In contrast to the situation in children, bullous or necrotic cutaneous lesions were found in about 60% of adults with HSP in Tancrede-Bohin's series [9]. Nevertheless, 16% (12/77) of adults with HSP were noted to have blisters in another series reported by Cream et al [13]. The 2 cases in our report had short and self-limited course, like most other children with HSP. The presence of such lesions seems not to be a prognostic factor in children with HSP. However, our report reminds clinicians that hemorrhagic bullae may be one of the cutaneous manifestations of HSP, and skin biopsies can be unnecessary for diagnosis in such a situation.

The role of corticosteroid therapy in HSP is controversial. Corticosteroids may hasten the resolution of arthritis and abdominal pain but have no apparent effect on the rashes [1]. Accordingly, corticosteroids are not recommended for rashes alone. However, major manifestations of localized vasculitis in the lungs, testes and central nervous system should be treated with corticosteroids [2]. On the other hand, we should exclude other conditions that are much more likely to be fatal than HSP but resemble it, such as meningococemia, before the use of corticosteroids. Broad-spectrum antibiotics can help prevent secondary bacterial infection once bullous lesions occur, which might easily rupture. In the 2 cases of our report, both suffered from prominent arthralgia combined with severe eruption, and corticosteroids were thus administered. Dramatic improvement of clinical symptoms and signs was observed within a few days after initiation of corticosteroid therapy. No recurrence was found in the following 6 months. Patients with HSP with similar manifestations might benefit from corticosteroid therapy as well.

References

1. Saulsbury FT. Henoch-Schönlein purpura in children. Report of 100 patients and review of the literature. *Medicine* 1999;78:395-409.
2. Lanzkowsky S, Lanzkowsky L, Lanzkowsky P. Henoch-Schönlein purpura. *Pediatr Rev* 1992;13:130-7.
3. Mills JA, Michel BA, Bloch DA, Calabrese LK, Hunder GG, Arend WP, et al. The American College of Rheumatology 1990 criteria for the classification of Henoch-Schönlein purpura. *Arthritis Rheum* 1990;8:1114-21.
4. Giangiacomo J, Tsai CC. Dermal and glomerular deposition of IgA in anaphylactoid purpura. *Am J Dis Child* 1977;131:981-3.
5. Blanco R, Martinez-Taboada VM, Rodriguez-Valverde V, Garcia-Fuentes M, Gonzalez-Gay MA, et al. Henoch-Schönlein purpura in adulthood and childhood. *Arthritis Rheum* 1997;40:859-64.
6. Rook A, Wilkinson DS, Ebling FJ. *Textbook of dermatology*. 2nd ed. London: Blackwell Co; 1972:940-2.
7. Nussinovitch M, Prais D, Finkelstein Y, Varsano I. Cutaneous manifestations of Henoch-Schönlein purpura in young children. *Pediatr Dermatol* 1998;15:426-8.
8. Helander SD, de Castro FR, Gibson LE. Henoch-Schönlein purpura: clinicopathologic correlation of cutaneous vascular IgA depositions and the relationship to leukocytoclastic vasculitis. *Acta Derm Venereol* 1995;75:125-9.
9. Tancrede-Bohin E, Ochonisky S, Vignon-Pennamen MD, Flageul B, Morel P, Rybojad M. Schönlein-Henoch purpura in adult patients. Predictive factors for IgA glomerulonephritis in a retrospective study of 57 cases. *Arch Dermatol* 1997;133:438-42.
10. Saulsbury FT. Henoch-Schönlein purpura. *Curr Opin Rheumatol* 2001;13:35-40.
11. Saulsbury FT. Hemorrhagic bullous lesions in Henoch-Schönlein purpura. *Pediatr Dermatol* 1998;15:357-9.
12. Abdel-Al YK, Hejazi Z, Majeed HA. Henoch Schönlein purpura in Arab children. Analysis of 52 cases. *Trop Geogr Med* 1990;42:52-7.
13. Cream JJ, Gumpel JM, Peachey RD. Schönlein-Henoch purpura in the adult. A study of 77 adults with anaphylactoid or Schönlein-Henoch purpura. *Q J Med* 1970;39:461-84.