

Cyclosporin A therapy in a case with hyperimmunoglobulin E and nephrotic syndrome

Chin-Nam Bong¹, Shun-Chen Huang², Chih-Lu Wang³, Po-Mai Liu³, Hsin-Hsu Chen³, Kuender D. Yang³

¹Department of Pediatrics, Pingtung Christian Hospital, Pingtung; and Departments of ²Pathology and ³Pediatrics, Chang Gung Children's Hospital, Kaohsiung, Taiwan

Received: January 19, 2004 Revised: April 24, 2004 Accepted: May 24, 2004

We describe the beneficial effects of treatment with cyclosporin A in a 10-year-old boy with hyperimmunoglobulin E and refractory nephrotic syndrome. The patient was initially resistant to steroid therapy with prednisolone alone. Additional therapy with cyclosporin A was then prescribed, effectively reducing levels of serum immunoglobulin E and preventing flare up of nephrotic syndrome.

Key words: Cyclosporin A, hyperimmunoglobulin E syndrome, nephrotic syndrome, prednisolone

Hyperimmunoglobulin E (hyper-IgE) syndrome is an immunodeficiency syndrome characterized by chronic pruritic skin rash, recurrent *Staphylococcus aureus* infection, high levels of IgE and neutrophil chemotactic defect [1]. T cell dysfunction has been shown to result in the overproduction of IgE [2]. Although various symptoms have been identified in hyper-IgE syndrome, renal disease is rarely associated with it [3]. Here we report an unusual case in Taiwan, where a patient had hyper-IgE syndrome complicated with nephrotic syndrome. The patient was initially unresponsive to steroid therapy, but was effectively controlled with a combination of cyclosporin A (CsA) with a low dose of prednisolone.

Case Report

A 10-year-old boy had no significant family history of pruritic skin rash. He had intractable pruritic skin rash with excoriation, chronic coughing, sneezing, as well as a running nose since infancy. Several episodes of pyoderma and impetigo over the extremities, 1 episode of bacterial pneumonia and acute otitis medium were also noted. In July 1998, at the age of 5 years, he was first admitted to our ward because of pitting edema over the periorbital region and lower legs associated with excoriate rash. Typical facial and skeletal features of hyper-IgE syndrome are as follows: coarse-featured prominent forehead, wide alar base to the nose, wide

outer canthal distance, midline facial defect, retained primary teeth, long bone fractures. None of the above features were observed in this patient. No diminished lacrimal or salivary gland secretion resulting in keratoconjunctivitis sicca or xerostomia was identified. In addition, no malar rash or photosensitivity was observed. Growth and development were within a normal range.

Laboratory tests indicated eosinophilia, marked hypoalbuminemia, elevated cholesterol and triglyceride, as well as extremely high serum IgE levels: eosinophil, 881 cells/ μ L (normal range, <700); albumin, 1.6 g/dL (3.0-5.0); cholesterol, 542 mg/dL (109-189); triglyceride, 392 mg/dL (30-86); IgE, 11,900 IU/mL (5.7-85). Renal function was moderately impaired: 24-h urine creatinine clearance was 58.97 mL/min (97-137), urinary protein excretion was 4.4 g/day (<0.15), blood urea nitrogen was 18 mg/dL (5-18) and serum creatinine was 0.7 mg/dL (0.8-1.5). No auto-antibodies were found, and levels of complement C3 and C4 were within a normal range.

Neutrophil function study showed that the number of migrating cells toward chemotactic factor, N-formylmethionylleucylphenylalanine (FMLP) 10^{-8} M [4], was less than one-half of the normal control (Fig. 1), and was considered as a chemotactic defect according to our laboratory cumulative normal value. Based on the above findings, a diagnosis of hyper-IgE syndrome associated with nephrotic syndrome was made. He was then followed up at our outpatient clinic, receiving prednisolone therapy. However, due to frequent relapse of nephrotic syndrome, renal biopsy was performed in October 2000, revealing a minimal

Corresponding author: Dr. Kuender D. Yang, Department of Pediatrics, Chang Gung Children's Hospital, 123, Ta-Pei Road, Niao-sung Hsiang, Kaohsiung 833, Taiwan.
E-mail: bongchinmam@yahoo.com.tw

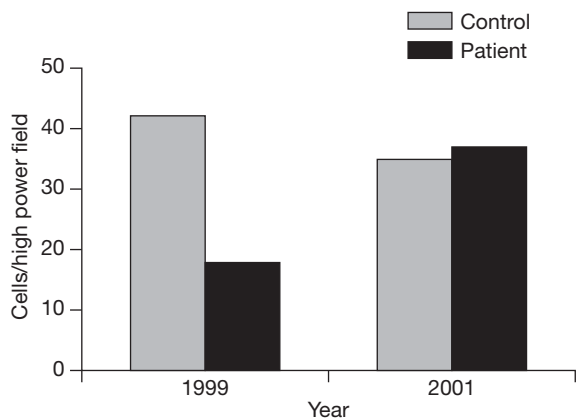


Fig. 1. Neutrophil chemotactic function was investigated by a micropore filter method. The number of migrating cells of the patient into the filter was less than one-half of the normal control (18 vs 42 cells/high power field) under stimulation of a synthetic chemotactic peptide, N-formylmethionylleucylphenylalanine 10^{-8} M in 1999. However, the number returned normal in 2001 (37 vs 35 cells/high power field), 1 year after cyclosporin A therapy.

change disease (MCD) [Fig. 2A]. Immunofluorescence study showed no deposits of IgG, IgA, IgM, C3, C4, C1q and fibrinogen (Fig. 2B). In addition, electron microscopic studies showed normal thickness of the basement membrane of the glomerular capillaries with diffuse effacement of foot process and villous hyperplasia of the cytoplasm of the epithelial cells (Fig. 2C). We began combination therapy with CsA 4 mg/kg/day and a low prednisolone dose of 0.5 mg/kg/day starting from October 2000. CsA blood concentration was closely monitored in order to maintain levels within a normal range (150-300 ng/mL). His neutrophil chemotactic function was back to normal 1 year after starting combination therapy (Fig. 1), and the level of serum IgE gradually reduced to 1920 IU/mL in July 2002 (Fig. 3). His skin cleared, and there was no relapse of nephrotic syndrome 6 months after combination therapy was started.

The patient also had a history of asthma and allergic rhinitis. Allergen tests showed multiple allergens, including *Dermatophagoides pteronyssinus*, common ragweed, cockroach and peanut. The patient received antiallergic drugs regularly.

The patient is currently followed up regularly at our outpatient department. The treatment course of this patient is summarized in Fig. 3. As shown in Fig. 3, prednisolone therapy was prescribed starting in July 1998, and the dosage was adjusted according to the clinical symptoms and urinalysis results. This patient was admitted to our hospital 6 times due to flare up of

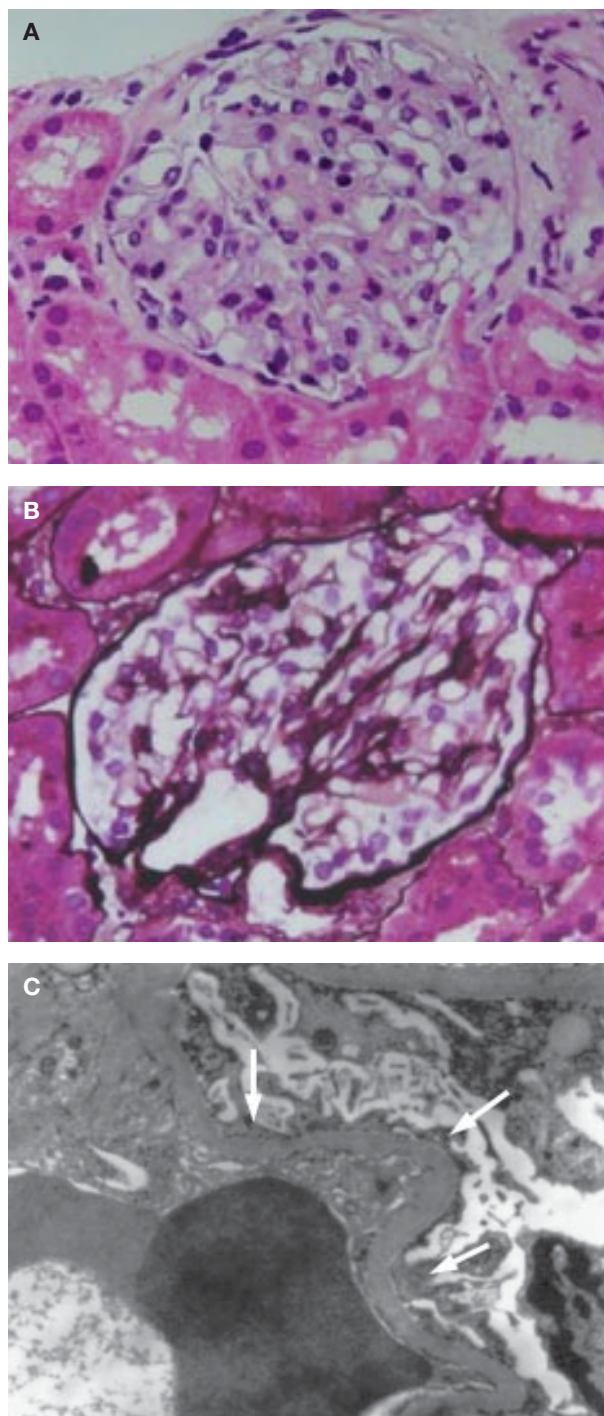


Fig. 2. Light micrographs of renal biopsy specimens. (A) The glomerular cellularity was normal, and the capillaries were slightly dilated. The capillary basement membranes were thin and delicate (hematoxylin and eosin stain, $\times 280$). (B) There was no deposit in the basement membranes or mesangial cell proliferation (periodic acid silver methenamine stain, $\times 350$). (C) Electron micrograph ($\times 4000$) showed normal thickness of glomerular basement membranes. No electron-dense deposits were seen. The foot processes of visceral epithelial cells showed diffuse effacement (arrows).

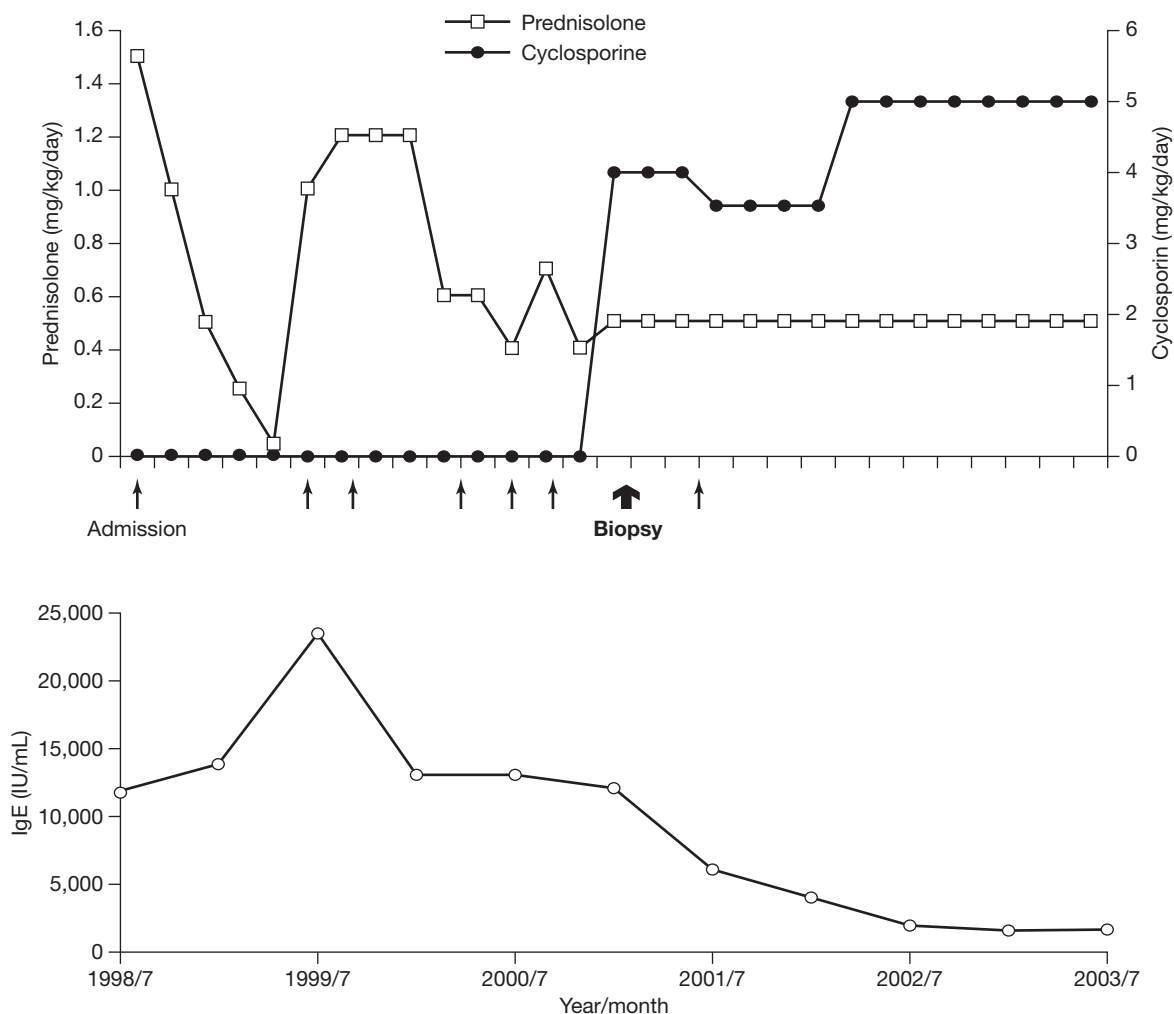


Fig. 3. Treatment course of the studied patient. Serum immunoglobulin E (IgE) levels and frequency of admission due to nephrotic syndrome reduced significantly after a combination of cyclosporin A with a low dose of prednisolone was prescribed.

nephrotic syndrome before starting combination therapy with CsA and a low dose of prednisolone in October 2000. Frequency of admission significantly reduced after combination therapy. The level of serum IgE also decreased to less than 2000 IU/mL in July 2002.

Discussion

Buckley et al first described hyper-IgE syndrome in 1972 [5]. It is referred to as Job's syndrome after an earlier report by Davis et al of 2 girls who had repeated episodes of skin infections in 1966 [6]. Hyper-IgE syndrome is a multi-system disorder, including immunologic, skeletal, dental and facial disorders. It was originally found to occur in red-haired Caucasian girls. However, more and more evidence has shown that this syndrome can occur in all ethnic groups. Its clinical

manifestations consist of *S. aureus*-related recurrent skin abscesses, pulmonary abscesses, extremely elevated levels of serum IgE, intractable pruritic eczema, as well as dysfunctional neutrophil chemotaxis [7,8]. Accompanying eosinophilia is also observed [9]. Usually, most of the infection occurs before 3 months of age in infancy. Infections include the following: recurrent cold abscesses, pneumonias, mucocutaneous candidiasis, otitis externa, otitis media, mastoiditis, gingivitis, and multiple caries. The chemotactic defect is not a constant feature and may vary within a patient over time [10]. The skeletal and facial abnormalities usually present after 16 years of age [8], which match the findings of the physical characteristics in this case. It has been found that 72% of patients have features of failure or delay in shedding of the primary teeth, owing to a lack of root resorption [11]. More than half

of patients have the following skeletal abnormalities: recurrent fractures, hyperextensible joints and scoliosis. Most cases of hyper-IgE syndrome are sporadic and equally distributed between males and females. It is worth noting that although serum IgE levels over 2000 IU/mL in patients younger than the age of 12 can be used as a screening standard, a normal serum IgE level in an adult should not exclude the presence of hyper-IgE syndrome, because the level of serum IgE may fall over time [11].

The cause of hyper-IgE syndrome is still unknown. It is believed that defects in T cells might be a major cause. One study showed a poor antibody response to immunization, suggesting a fundamental deficiency in immune response [12]. Other studies have shown that IgE synthesis is normally enhanced by T-helper 2 (Th2) cytokines interleukin-4 (IL-4) and IL-13, and repressed by T helper 1 (Th1) cytokines interferon- γ and IL-12 [13]. As the Th1 and Th2 cytokines act in opposition to each other, high serum IgE production is likely due to either a decreased Th1 response or an increased Th2 response.

Prophylactic antibiotics, skin care and prompt treatment of infection have been the mainstay of treatment for hyper-IgE syndrome. In this case, the initial therapy used was the corticosteroid prednisolone, under the consideration of associated nephrotic syndrome. Corticosteroids have been shown to not only inhibit the transcription of IL-1, tumor necrosis factor- α and IL-6 in macrophages, but also block antigen recognition [14]. Prednisolone has been shown to inhibit membranous type II IgE receptor (Fc ϵ R2/CD23) expression, which has been reported to be correlated with elevated serum IgE levels in minimal change nephrotic syndrome [15]. Therefore, corticosteroid therapy for nephrotic syndrome may be related to the balance among cytokine secretion, CD23 expression and serum IgE production. It is suggested that patients who do not respond to corticosteroid therapy, administration of cytotoxic therapy or CsA may induce remission [16].

It has been reported that CsA at a dose of 3 mg/kg/day in a 3-year-old boy with hyper-IgE syndrome produces dramatic improvements in the normalization of serum IgE levels within 6 months [17]. In our case, the normalization of serum IgE levels was not achieved after 1 year of administering CsA; perhaps the combined nephrotic syndrome in this patient complicated the acting pathway of CsA. The mechanisms of CsA on hyper-IgE syndrome remain unknown;

however, some investigators have suggested possible mechanisms of CsA in nephrotic syndrome [18,19]. CsA binds to endogenous intracellular receptors and the immunophilins. The resulting complex inhibits calcineurin and subsequent formation of a factor essential for transcription of the IL-2 or IL-2 receptor (IL-2R) gene, thereby decreasing the production of IL-2 and expression of IL-2R from the activated T cell. The synergetic blocking effect of CsA explains the advantage of using combined therapy in our case.

Nephrotic syndrome represents the physiologic consequences of massive urinary protein loss, leading to hypoalbuminemia, edema and hyperlipidemia. MCD is the most common nephrotic syndrome in children. The cause of MCD is unknown, but the disease may be preceded by viral infection, allergic reactions or recent immunization [16]. T cell disorder has been shown in some cases of primary glomerulonephritis with high serum IgE, especially in MCD, which causes an abnormal regulation of IgE synthesis by a shift to Th2 lymphocytes [20-22]. It is also postulated that the decrease of serum IgE levels is related to clinical improvements in the MCD [23]. This indicates that IgE levels may be a useful index of disease activity of hyper-IgE syndrome with nephrotic syndrome. Different immunologic alterations in various patients with nephrotic syndrome may require different treatment regimens.

In conclusion, nephrotic syndrome associated with imbalanced Th1 and Th2 reaction and elevated serum IgE levels may cause renal histologic damage and require immunomodulation therapy other than classical steroid treatment. We suggest that CsA is beneficial in certain patients with hyper-IgE and refractory nephrotic syndrome through an unidentified mechanism. It could be considered for use in some severe cases of hyper-IgE and nephrotic syndrome where other therapeutic modalities have failed.

References

1. Buckley RH. Disorders of the IgE system. In: Stiehm ER, Fulginiti VA, eds. Immunologic disorder in infants and children. 2nd ed. Philadelphia: W. B. Saunders Co.; 1980:274-85.
2. Geha RS, Reinherz E, Leung D, McKee KT Jr, Schlossman S, Rosen FS. Deficiency of suppressor T cells in the hyperimmunoglobulin E syndrome. *J Clin Invest* 1981;68: 783-91.
3. Tanji C, Yorioka N, Kanahara K, Naito T, Oda H, Ishikawa K, et al. Hyperimmunoglobulin E syndrome associated with nephrotic syndrome. *Intern Med* 1999;38:491-4.

4. Zigmond SH. Ability of polymorphonuclear leukocytes to orient in gradients of chemotactic factors. *J Cell Biol* 1977;75: 606-16.
5. Buckley RH, Wray BB, Belmaker EZ. Extreme hyperimmunoglobulinemia E and undue susceptibility to infection. *Pediatrics* 1972;49:59-70.
6. Davis SD, Schaller J, Wedgwood RJ. Job's syndrome. Recurrent "cold" staphylococcal abscesses. *Lancet* 1966;1: 1013-5.
7. Gallin JI, Wright DG, Malech HL, Davis JM, Klempner MS, Kirkpatrick CH. Disorder of phagocyte chemotaxis. *Ann Intern Med* 1980;92:520-38.
8. Erlewyn-Lajeunesse, Michel DS. Hyperimmunoglobulin-E syndrome with recurrent infection: a review of current opinion and treatment. *Pediatr Allergy Immunol* 2000;11:133-41.
9. Buckley RH. Disorder of IgE system. In: Stiehm ER, Fulginiti VA, eds. *Immunological disorders in infants and children*. 2nd ed. Philadelphia: W. B. Saunders Co.; 1996:409-22.
10. Donabedian H, Gallin JI. The hyperimmunoglobulin-E recurrent infection (Job's) syndrome: A review of the NIH experience and the literature. *Medicine* 1983;62:195-208.
11. Grimbacher B, Holland SM, Gallin JI, Greenberg F, Hill SC, Malech HL, et al. Hyper-IgE syndrome with recurrent infections – an autosomal dominant multisystem disorder. *N Engl J Med* 1999;340:692-702.
12. Matsumoto T, Gotoh Y, Narukami H, Miyamoto Y, Honda M. A hyperimmunoglobulin E syndrome with serum inhibitor against immune functions. *Ann Allergy* 1981;46:86-8.
13. Borges WG, Augustine NH, Hill HR. Defective interleukin-12/interferon-gamma pathway in patients with hyperimmunoglobulinemia E syndrome. *J Pediatr* 2000;136:176-80.
14. Brann DW, Hendry LB, Mahesh VB. Emerging diversities in the mechanism of action of steroid hormones. *J Steroid Biochem Mol Biol* 1995;52:113-33.
15. Cho BS, Yoon SR, Jang JY, Pyun KH, Lee CE. Up-regulation of interleukin-4 and CD23/FcepsilonRII in minimal change nephrotic syndrome. *Pediatr Nephrol* 1999;13:199-204.
16. Robinson RF, Nahata MC, Mhan JD, Batisky DL. Management of nephrotic syndrome in children. *Pharmacotherapy* 2003;23: 1021-36.
17. Etzioni A, Shehadeh N, Brecher A, Yorman S, Pollack S. Cyclosporine A in hyperimmunoglobulin E syndrome. *Ann Allergy Asthma Immunol* 1997;78:413-4.
18. O'Keefe SJ, Tamura J, Kincaid RL, Tocci MJ, O'Neill EA. FK506 and CsA-sensitive activation of the interleukin-2 promoter by calcineurin. *Nature* 1992;357:692-4.
19. Toshihiko H, Takao A, Takayuki K, Kitaro O, Noriko I, Masaharu Y. Clinical impact of cyclosporine cellular pharmacodynamics in minimal change nephritic syndrome. *Clin Pharmacol Ther* 2000;68:532-40.
20. Groshong T, Mendelson L, Mendoza S, Bazaral M, Hamburger R, Tune B. Serum IgE in patients with minimal-change nephrotic syndrome. *J Pediatr* 1973;83:767-71.
21. Shu KH, Lian JD, Lu YS, Chen CH, Tsai DY, Chao KS, et al. Immunoglobulin-E-specific suppressor factors in primary glomerulonephritis with nephrotic syndrome. *Nephron* 1992; 60:432-5.
22. Wardle EN. Minimal change nephrosis and allergy. *Nephron* 1996;74:422-3.
23. Shu KH, Lian JD, Yang YF, Lu YS, Wang JY. Serum IgE in primary glomerular diseases and its clinical significance. *Nephron* 1988;49:24-8.