

An unusual case of ulcerative colitis with concurrent extraintestinal manifestations of primary sclerosing cholangitis, thromboembolism, hemolytic anemia, and hemochromatosis

Cheng-Han Wu¹, Jau-Min Wong², Song-Chou Hsieh¹, Chia-Li Yu¹

Divisions of ¹Allergy, Immunology and Rheumatology and ²Gastroenterology, Department of Internal Medicine, National Taiwan University Hospital, Taipei, Taiwan

Received: April 7, 2004 Revised: April 16, 2004 Accepted: July 9, 2004

Inflammatory bowel disease (IBD) is a chronic inflammatory disorder of intestines associated with a large number of extraintestinal manifestations (EIMs) which significantly contribute to its morbidity and mortality. A 32-year-old man presented with ulcerative colitis (UC) accompanied by the unusual coexisting clinical manifestations of primary sclerosing cholangitis, thromboembolism, and hemolytic anemia during the disease course. The incidental finding of hemochromatosis of the liver was attributed to chronic hemolysis. The full-blown EIMs and systemic complications in this patient did not appear to be attributable to drug treatment and/or infection but might have been related to both the underlying immune-mediated mechanism and the lack of early and adequate treatment for UC and its associated complications. This case emphasizes the need for early and aggressive treatment of IBD accompanied by EIMs to avoid morbidity and mortality.

Key words: Hemochromatosis, hemolytic anemia, sclerosing cholangitis, thromboembolism, ulcerative colitis

Inflammatory bowel disease (IBD) is a multifactorial polygenic chronic inflammatory disease [1-3] that predominantly affects the gastrointestinal system, with the potential for systemic involvement. Extraintestinal manifestations (EIMs) involving almost every organ system have been reported in 21-36% of patients with IBD and occur more frequently with increasing duration or extent of the disease [3-6]. Multiple EIMs in the same patient are not uncommon and are observed more frequently than would be expected by chance alone [3, 7]. EIMs and systemic complications may precede, accompany, or follow IBD, usually complicating the management of the underlying disease and contributing significantly to morbidity and mortality [7].

In patients with IBD, hepatobiliary manifestations [8] and thromboembolic events [9] are rare but serious extraintestinal complications leading to significant morbidity and mortality. Although anemia, usually secondary to chronic intestinal blood loss and associated iron deficiency, persistent inflammation, nutritional

deficiencies, or adverse effect of immunosuppressive agents, is common in IBD [3,5,7,10,11], autoimmune hemolytic anemia (AIHA) is rarely reported [3,12]. Herein we report a case of ulcerative colitis (UC) accompanied by the unusual coexisting clinical manifestations of primary sclerosing cholangitis (PSC), thromboembolism, and hemolytic anemia in the disease course. The incidental finding of liver hemochromatosis was attributed to chronic hemolysis. The full-blown EIMs and systemic complications of UC in this patient might have been directly related to both the underlying immune-mediated mechanism and the absence of early and adequate treatment. IBD and EIMs are actually systemic in nature and must be treated early and aggressively to avoid morbidity and mortality.

Case Report

A 32-year-old man was admitted in March 2002 due to gradual onset of shortness of breath for 6 months and persistent jaundice for several weeks. He had a 14-year history of UC, which had been controlled with Asacol (mesalazine) 1.2 g/day and prednisolone 5 mg/day for many years. However, abdominal fullness and watery diarrhea had developed and persisted since June 2001.

*Corresponding author: Chia-Li Yu, M.D., Ph.D., Division of Allergy, Immunology and Rheumatology, Department of Internal Medicine, National Taiwan University Hospital, No. 7 Chung-Shan South Road, Taipei 100, Taiwan.
E-mail: clyu@ha.mc.ntu.edu.tw*

The dosage of Asacol was increased to 1.6 g/day with poor response. Four months later, he visited our gastroenterology clinic because of severe bloody diarrhea. Colonoscopy revealed diffuse edema and friability of the whole colon mucosa. A 1-month course of Asacol at a dosage of 2.4 g/day was given with no response. He was then treated with Pentasa (mesalazine) 4 g/day since November 2001 and bloody diarrhea subsided. However, jaundice, which had been intermittent since the age of 18, had worsened in recent weeks and did not subside completely even after endoscopic retrograde cholangiopancreatography (ERCP) was performed for extraction of common bile duct (CBD) stones in February 2002. Packed red blood cell (RBC) transfusion had also been given at least 3 times during the past 4 months due to decreased hemoglobin (Hb) level which ranged from 6.5-8 g/dL before each transfusion. Ten days prior to starting Pentasa, his Hb level was 10.5 g/dL, mean corpuscular volume (MCV) 115.9 fL (normal range, 80-100 fL), white blood cell (WBC) count 9930/mm³, platelet count 861,000/mm³, normoblast 19/100 WBCs, total bilirubin 3.43 mg/dL, direct bilirubin 0.2 mg/dL, while aspartate aminotransferase (AST) and alanine aminotransferase (ALT) levels were within normal limits.

On admission, he had jaundice, hepatomegaly and clubbing of the fingers, but no other symptoms/signs of EIMs involving the joints, skin, mouth or eyes. Laboratory study revealed macrocytic anemia (Hb 8.1 g/dL, MCV 122.2 fL) with reticulocytosis (reticulocyte 7.7% of RBC, normoblast 6/100 WBCs), thrombocytosis (platelets 888,000/mm³), leukocytosis (WBC 14,650/mm³), mixed hyperbilirubinemia (total bilirubin 4.4 mg/dL, direct bilirubin 2.1 mg/dL), and active inflammation. Alkaline phosphatase was 379 U/L (normal, 60-220 U/L), γ -glutamyl transferase (γ -GT) 287 U/L (normal, 0-52 U/L), haptoglobin 189 mg/dL (normal, 64.81-157.48 mg/dL), erythrocyte sedimentation rate 38 mm/h, C-reactive protein 7.24 mg/dL (normal, <0.8 mg/dL), and stool occult blood +++. The values of AST, ALT, lactate dehydrogenase (LDH), and cholesterol were within normal limits. The corrected reticulocyte production index ranged from 1.8-2.3%. Serologic examinations were negative for anti-nuclear antibodies, hepatitis B surface antigen, and anti-hepatitis C virus and anti-human immunodeficiency virus antibodies. The values of C3, C4, immunoglobulin (Ig) A, IgG, and IgM were within normal limits. The myeloperoxidase anti-neutrophil cytoplasmic antibody (ANCA) level was

8.7 U/mL (borderline range, 7-15 U/mL) and proteinase 3 ANCA was negative.

Pulmonary embolism (PE) with pulmonary hypertension was diagnosed after evaluation of D-dimers, chest X-ray, cardiac echo, lung perfusion and ventilation scan. Venous duplex also suggested partial thrombosis of the left common femoral vein. Protein C antigen level was 71% (normal, 72-174%) and functional protein C level was 50% (normal, 70-192%). Prothrombin time, activated partial thromboplastin time, protein S and anti-thrombin III level were all in the normal range. Except for smoking, he had no other common risk factors for thromboembolism. Because endoscopy revealed superficial gastritis and active duodenal ulcer, no anticoagulant was given. Dyspnea improved gradually after conservative treatment. Abdominal ultrasonography and subsequent magnetic resonance cholangiopancreatography (MRCP) revealed parenchymal liver disease, luminal outline irregularity with stricturing of both CBD and bilateral intrahepatic ducts (IHDs), 1 gallbladder stone, 1 left IHD stone, portal vein thrombosis, and invisible spleen. MRCP also revealed marked low signal of nearly the whole liver. His father also had history of iron deposition in multiple organs including liver, and had died of hepatoma. Iron overload of the liver and sclerosing cholangitis were highly suspected. Because of fever, he received intravenous antibiotics and endoscopic nasobiliary drainage of bile due to suspicion of biliary tract infection. Two days later, ERCP with balloon lithotripsy of CBD stones was performed. After excluding other causes of sclerosing cholangitis, PSC was confirmed by cholangiography (Fig. 1). Scintigraphy of the liver and spleen confirmed asplenism and histology of liver tissue demonstrated portal inflammation and hemochromatosis (Fig. 2).

Blood film disclosed macrocytosis, anisocytosis, poikilocytosis, basophilic stippling, polychromatophilia, and few target cells. Reticulocytosis and possible hemoglobinopathy were suspected, but Hb electrophoresis revealed no abnormalities. Bone marrow aspiration and biopsy revealed erythroid hyperplasia and megakaryocyte hyperplasia. The presence of thrombocytosis and leukocytosis was attributed to asplenism and chronic inflammation. Blood iron level was 41 μ g/dL (normal, 51-180 μ g/dL), total iron binding capacity 184 μ g/dL (normal, 275-332 μ g/dL), and ferritin 1695 ng/mL (normal, 17.9-464 ng/mL). He had no glucose-6 phosphate dehydrogenase deficiency and tests of vitamin B₁₂, folic acid, thyroid and adrenal

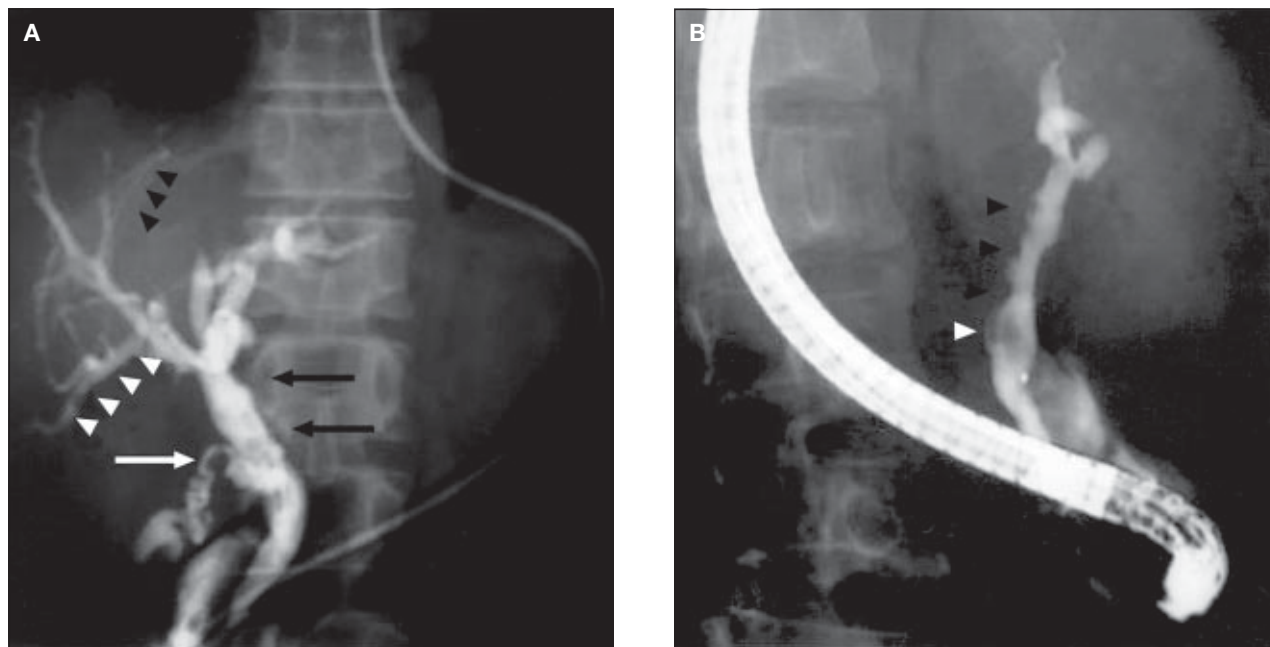


Fig. 1. (A) Cholangiography shows pruning of intrahepatic ducts (IHDs), irregular common bile duct (CBD) contour with diverticulum-like out-pouching (arrows), multiple irregular stricturing and saccular dilatation of 1 IHD (white arrowheads), and diffuse narrowing of another IHD (arrowheads). Low insertion of a cystic duct (white arrow) is also noted. (B) In another view, irregular stricturing with rigidity of the CBD wall are obvious (arrowheads). There are also 2 filling defects seen in the CBD (white arrowhead).

function, and sugar water test showed normal results. RBC osmotic fragility test showed decreased fragility. Coombs' test (direct or indirect) was negative or trace positive in repeated examinations. Two weeks after admission, AST level was 99 U/L (normal, 5-31 U/L), ALT 56 U/L (normal, 0-41 U/L), and LDH 540 U/L (normal, 230-460 U/L). These results, together with the history of indirect hyperbilirubinemia and the absence of other causes of macrocytic anemia, led to the diagnosis of hemolytic anemia accompanied by reticulocytosis. Treatment with Pentasa was discontinued in April 2002, and prednisolone 10 mg/day and Asacol 2.4 g/day were given to control bowel activity. Blood transfusion was not required thereafter and Hb level returned to 11.2 mg/dL 1 month later. He stopped cigarette smoking, and during follow-up visits at the hematologic clinic, hydroxyurea was given for persistent thrombocytosis and desferoxamine for hemochromatosis. He was again admitted several times for recurrent PE and received either oral warfarin or subcutaneous low-molecular-weight heparin. There was no serologic evidence of antiphospholipid antibody syndrome as shown by negative results for anti-cardiolipin antibody, anti-phospholipid antibody and lupus anticoagulant. Carcinoembryonic antigen level (0.97 ng/mL) was also within normal limits and there was no image/pathology evidence to suggest UC-associated colon cancer. In

January 2003, chest computed tomography demonstrated marked thrombus in the bilateral pulmonary artery. Reticulocytosis was still noted in April 2003. At this time, Hb level was 12.9 mg/dL, MCV 128.5 fL, WBC 18,950/mm³, platelets 397,000/mm³, and normoblast 8/100 WBCs. He died of recurrent PE several weeks later in another hospital.

Discussion

EIMs associated with IBD are quite common and may increase morbidity and mortality significantly. Patients with IBD had a 3-fold increased risk of thromboembolic complications compared with the general population [13]. Most IBD patients had active disease at the time of acute deep venous thrombosis (DVT)/PE. Extensive involvement in UC, particularly pancolonic involvement, was associated with a higher risk of thromboembolism [14]. In a study from Mayo Clinic [9], the incidence of thromboembolism was 1.3% in IBD patients, and 66% of these patients had DVT or PE. Portal and mesenteric thrombosis were also noted in 8.7% of IBD patients with thromboembolism. Moreover, about 77% of DVT or PE had no other precipitating factors except underlying IBD. Thromboembolism led to a 25% mortality rate in IBD patients, and recurrent thromboembolic episodes were not uncommon (about

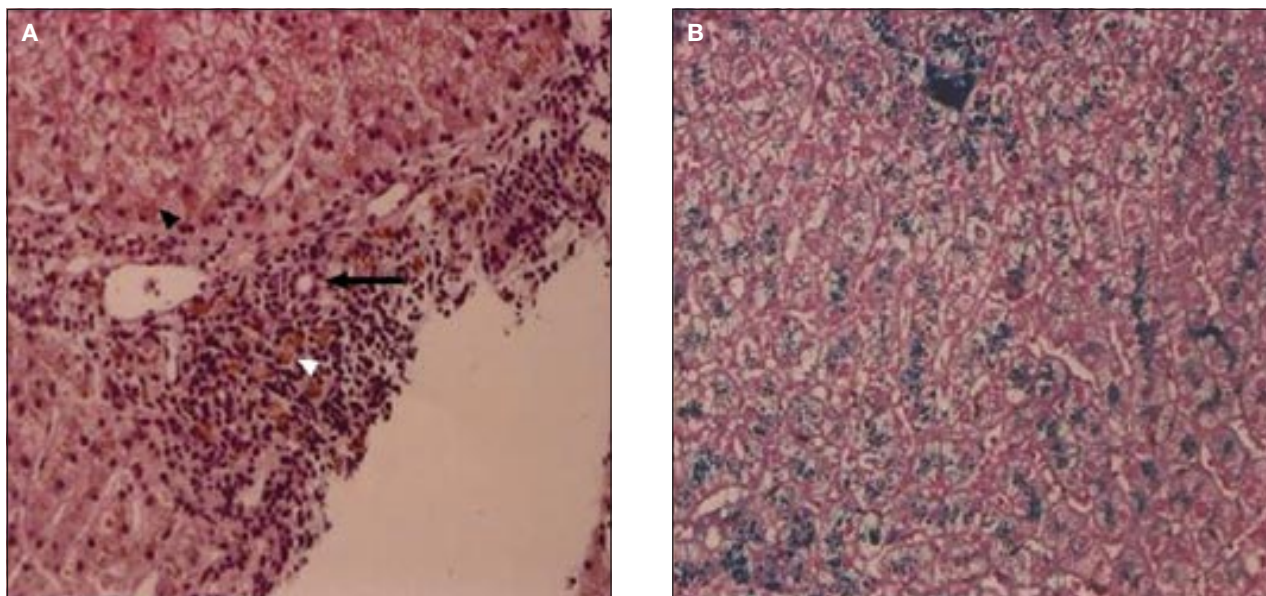


Fig. 2. (A) Hepatic histology reveals numerous hemosiderin-like brown granules in hepatocytes (arrowhead) and in the portal macrophages (white arrowhead). Marked lymphocytes infiltration is apparent in the portal area. Neither the portal area nor the bile duct (arrow) shows sclerotic change (hematoxylin and eosin stain; original magnification, $\times 100$). (B) Iron stain of the liver confirms the presence of abundant iron granules (iron stain; original magnification, $\times 200$).

10%) [9,14]. These thromboembolic episodes have been largely attributed to hypercoagulability due to abnormalities of platelets and coagulation cascades [5,9,14,15]. In our patient, there was no evidence of antiphospholipid antibody syndrome or colon cancer, and cigarette smoking, thrombocytosis and protein C deficiency was likely to have been a greater factor in the development of peripheral DVT, portal vein thrombosis, and PE. Because thrombocytosis might have been related to the asplenism and chronic inflammation of UC, control of the colitis, lowering the platelet count, and anticoagulant therapy were the main strategies used to prevent or reduce the risk and mortality of thromboembolism in our patient.

Routine screening with biochemical profiles and widespread application of ERCP have led to the significant increase in the recognition of PSC [16]. Among patients with PSC, 50-75% have IBD [8], in which UC is much more commonly associated (48% to 82%, mean 67%) [17]. However, the prevalence of PSC in IBD patients is low, ranging from 2.4-7.5% only. PSC predominantly affects young males and can be asymptomatic with normal or minimal elevation of serum alkaline phosphatase [8]. In fact, PSC is the most common and serious hepatic and biliary disorder occurring in association with IBD [17] and it should be considered first in IBD patients with elevated serum level of alkaline phosphatase [18]. Recently, primary

biliary cirrhosis (PBC) has also been reported in patients with UC [19,20] and it should be differentiated from the more common finding of PSC. In addition to the characteristic features of PSC in our patient, there was also an absence of the typical findings of PBC, including skin pruritus, hypercholesterolemia, increased IgM level, normal cholangiogram and hepatic granuloma formation [19,20].

Although elevated alkaline phosphatase and γ -GT were found in this patient, these abnormalities could be present in both PSC and PBC. Currently, ERCP is the preferred method for the diagnosis of PSC, but MRCP is likely to become the non-invasive diagnostic method of choice in the future [21]. However, ERCP has an additional therapeutic advantage in the management of CBD stones. Hepatic histology is another useful diagnostic adjunct of PSC and is recommended when ERCP yields no conclusive diagnosis [8]. The absence of bile ducts proliferation or fibrosis in our patient might have been related to the early course of the disease [22], low diagnostic rate [23], sampling variability of histopathology [24], or associated with the large duct variant of PSC with only minimal or nonspecific changes [17]. Although PSC is strongly associated with UC, there is no relation to the onset, duration, extent, or activity of colitis [4,7]. There is also no effective medical treatment for PSC, although therapy can be directed at the associated complications [8,25].

Hemolysis in our patient was not suggested by precipitating factors such as drugs, infection, hereditary RBC defect, malignancy, or other autoimmune disorder, except for underlying UC. Control of colitis activity is crucial to the control of UC-associated AIHA [12]. Our patient had a history of severe hemolytic anemia requiring blood transfusion which was often present during the period of active colitis and improved with the subsidence of UC activity after treatment with increased dosage of prednisolone and Asacol. UC-associated AIHA might have accounted for his elevated haptoglobin level and the intermittent jaundice in previous years.

In addition to the remission of UC, his asplenism might also have contributed to the good response to low-dose prednisolone treatment. Although genetic study was not performed in the patient and his father, the hemochromatosis of the liver as well as the intermittent jaundice were probably secondary to underlying immune-mediated hemolysis. Our review of the literature revealed only 1 previous case report of the unusual concurrent presentation of hereditary hemochromatosis (HH), UC, and PSC in a family [26]. In that report, the author also stated that there were no epidemiologic data in the literature linking HH to UC, or vice versa. Regardless of the cause of hemochromatosis, iron overload must be treated to reduce the parenchymal deposition and subsequent organ damage [27].

In summary, we report an unusual case of UC accompanied by the rare clinical features of thromboembolism, PSC, biliary stones, hemolytic anemia and other hematologic abnormalities, asplenism, and hemochromatosis. IBD is a systemic autoimmune disease associated with a great variety of EIMs and must be treated early and aggressively to avoid morbidity and mortality.

References

- Podolsky DK. Inflammatory bowel disease. *N Engl J Med* 2002; 347:417-29.
- Farrell RJ, Peppercorn MA. Ulcerative colitis. *Lancet* 2002; 359:331-40.
- Lakatos L, Pandur T, David G, Balogh Z, Kuronya P, Tollas A, et al. Association of extraintestinal manifestations of inflammatory bowel disease in a province of western Hungary with disease phenotype: results of a 25-year follow-up study. *World J Gastroenterol* 2003;9:2300-7.
- Das KM. Relationship of extraintestinal involvements in inflammatory bowel disease: new insights into autoimmune pathogenesis. *Dig Dis Sci* 1999;44:1-13.
- Su CG, Judge TA, Lichtenstein GR. Extraintestinal manifestations of inflammatory bowel disease. *Gastroenterol Clin North Am* 2002;31:307-27.
- Veloso F, Carvalho J, Magro F. Immune-related systemic manifestations of inflammatory bowel disease. A prospective study of 792 patients. *J Clin Gastroenterol* 1996;23:29-34.
- Rankin GB. Extraintestinal and systemic manifestations of inflammatory bowel disease. *Med Clin North Am* 1990;74: 39-50.
- Raj V, Lichtenstein DR. Hepatobiliary manifestations of inflammatory bowel disease. *Gastroenterol Clin North Am* 1999;28:491-513.
- Talbot RW, Heppell J, Dozois RR, Beart RW Jr. Vascular complications of inflammatory bowel disease. *Mayo Clin Proc* 1986;61:140-5.
- Gasche C. Complications of inflammatory bowel disease. *Hepatogastroenterology* 2000;47:49-56.
- Ardizzone S, Porro GB. Comparative tolerability of therapies for ulcerative colitis. *Drug Saf* 2002;25:561-82.
- Ramakrishna R, Manoharan A. Auto-immune haemolytic anaemia in ulcerative colitis. *Acta Haematol* 1994; 91:99-102.
- Bernstein CN, Blanchard JF, Houston DS, Wajda A. The incidence of deep venous thrombosis and pulmonary embolism among patients with inflammatory bowel disease: a population-based cohort study. *Thromb Haemost* 2001;85:430-4.
- Solem CA, Loftus EV, Tremaine WJ, Sandborn WJ. Venous thromboembolism in inflammatory bowel disease. *Am J Gastroenterol* 2004;99:97-101.
- Webberley MJ, Hart MT, Melikian V. Thromboembolism in inflammatory bowel disease: role of platelets. *Gut* 1993;34: 247-51.
- Summerfield J. Primary sclerosing cholangitis. *Postgrad Med J* 1983;59 Suppl 4:99-105.
- Balan V, LaRusso NF. Hepatobiliary disease in inflammatory bowel disease. *Gastroenterol Clin North Am* 1995;24:647-69.
- Lindor KD, Wiesner RH, MacCarty RL, Ludwig J, LaRusso NF. Advances in primary sclerosing cholangitis. *Am J Med* 1990;89:73-80.
- Lever E, Balasubramanian K, Condon S, Wat BY. Primary biliary cirrhosis associated with ulcerative colitis. *Am J Gastroenterol* 1993;88:945-7.
- Xiao WB, Liu YL. Primary biliary cirrhosis and ulcerative colitis: a case report and review of literature. *World J Gastroenterol* 2003;9:878-80.
- Ghosh S, Shand A, Ferguson A. Ulcerative colitis. *BMJ* 2000; 320:1119-23.
- Lillemoie KD, Pitt HA, Cameron JL. Primary sclerosing cholangitis. *Surg Clin North Am* 1990;70:1381-402.

23. Chapman RW, Arborgh BA, Rhodes JM, Summerfield JA, Dick R, Scheuer PJ, et al. Primary sclerosing cholangitis: a review of its clinical features, cholangiography, and hepatic histology. *Gut* 1980;21:870-7.
24. Olsson R, Hagerstrand I, Broome U, Danielsson A, Jarnerot G, Loof L, et al. Sampling variability of percutaneous liver biopsy in primary sclerosing cholangitis. *J Clin Pathol* 1995; 48:933-5.
25. Lamers CB. Treatment of extraintestinal complications of ulcerative colitis. *Eur J Gastroenterol Hepatol* 1997;9:850-3.
26. Ponsioen CY, Stokkers PC, vd Horst AR, Tytgat GN, van Deventer SJ. A patient with hereditary hemochromatosis, ulcerative colitis, and primary sclerosing cholangitis: genetic aspects. *Eur J Intern Med* 2001;12:518-21.
27. Andrews NC. Disorders of iron metabolism. *N Engl J Med* 1999;341:1986-95.