

## Brain abscesses in children: analysis of 20 cases presenting at a medical center

Kai-Liang Kao<sup>1,2</sup>, Keh-Gong Wu<sup>1</sup>, Chun-Jen Chen<sup>1</sup>, Jionn-Jong Wu<sup>3</sup>, Ren-Bin Tang<sup>1</sup>,  
Kai-Ping Chang<sup>1</sup>, Tai-Tong Wong<sup>4</sup>

<sup>1</sup>Department of Pediatrics, Taipei Veterans General Hospital and National Yang-Ming University;

<sup>2</sup>Department of Pediatrics and <sup>3</sup>Department of Surgery, Service of Neurosurgery,  
Far Eastern Memorial Hospital; and <sup>4</sup>Department of Neurosurgery,

Taipei Veterans General Hospital and National Yang-Ming University, Taipei, Taiwan

Received: May 12, 2007 Revised: June 1, 2007 Accepted: July 31, 2007

**Background and Purpose:** Brain abscess is an uncommon intracranial suppuration, especially in children. We reviewed the records of children with brain abscess admitted to Taipei Veterans General Hospital, Taipei, Taiwan, and analyzed data on presenting symptoms, predisposing factors and outcomes.

**Methods:** Information was obtained retrospectively from medical records of children diagnosed with brain abscess. Demographic data, presenting symptoms, predisposing factors, sites of abscess, infectious organisms, treatment regimen, and prognosis were collected and analyzed.

**Results:** Twenty cases of brain abscess within an 11-year period were included in this study. Fever, seizure and focal neurological deficits were the most common presenting symptoms. Cyanotic congenital heart disease (CCHD), present in 35% of patients, was the most common predisposing factor. *Staphylococcus aureus* was the most common pathogen. Approximately two-thirds of cases followed up had some form of seizure disorder sequelae; such sequelae were more common in patients with the initial presentation of seizure.

**Conclusion:** CCHD was the most common predisposing factor for brain abscess in children, and a high level of seizure disorder sequelae was noted. Children suffering from brain abscess, whose initial presentation reveals seizure, are at increased risk of further seizure disorder.

**Key words:** Brain abscess; Child; Heart defects, congenital; Seizures; Treatment outcome

### Introduction

Brain abscesses are rather uncommon in children, although they do represent the most common cause of pediatric intracranial suppuration [1]. Brain abscesses can develop as the result of a direct spread of an existing abscess from contiguous anatomic structures, via metastatic spread from a remote site, following certain surgeries, or as a consequence of certain traumatic injuries to the skull [2-4]. From the results of several earlier studies, however, no probable sources of brain abscess were able to be identified for up to 20% of

all reported cases [5]. There are few reports from Taiwan regarding the presentation of this rare disease, especially in children [6,7]. In order to improve understanding of the relationship between infectious disease and brain abscess in children, we collected and analyzed retrospective patient data from children with this condition who were diagnosed and treated at Taipei Veterans General Hospital, Taipei, Taiwan.

### Methods

We reviewed the medical records of children who had been diagnosed with brain abscess and treated at the Taipei Veterans General Hospital, Taipei, Taiwan, during an 11-year period from January 1996 to November 2006. The definition of brain abscess

Corresponding author: Dr Keh-Gong Wu, Department of Pediatrics, Taipei Veterans General Hospital, No. 201, Sec. 2, Shih-Pai Road, Taipei 112, Taiwan.  
E-mail: gkl.123@yahoo.com.tw

included the characteristic appearance of one or more localized lesions within the patient's brain, as determined from the findings of computed tomography, and/or as confirmed by histopathological investigation subsequent to surgery. Patients were excluded if the location of their abscess was in the subdural or epidural regions, and if they featured a history of prior head surgery or skull fracture. The relevant details of study participants were reviewed. Patient details reviewed included general patient characteristics, symptoms present upon initial presentation, underlying medical conditions, predisposing factors, location of abscesses, microorganisms isolated, treatment regimen, prognosis, and treatment outcome. The relationship between patient outcome and initial presentation and treatment was also analyzed.

### Statistical analysis

Statistical data were analyzed by Fisher's exact test, using the Statistical Package for the Social Sciences (SPSS) for Windows (Version 14.0; SPSS, Chicago, IL, USA). A *p* value less than 0.05 was considered statistically significant.

## Results

### General characteristics

We reviewed the medical records of 20 children, whose ages ranged from 20 days to 18 years (mean, 7.1 ± 6.2 years). All of these individuals were Han Chinese, with a male-to-female ratio of 0.82. Study participant gender and age distributions are presented in Fig. 1. Seventy five percent of patients were younger than 10 years.

### Presenting symptoms and signs

Major presenting symptoms and signs are summarized in Table 1. Fever was the most common initial presentation and was noted in 15 children (75%). Focal neurological deficits were the second most common presenting symptoms, being noted in 11 of the 20 cases (55%). Among the 11 children suffering conditions associated with focal neurological deficits, 8 cases featured hemiparesis, 2 featured ptosis, and 1 exhibited slurred speech.

Seizure attack was also a common initial presentation (50%), although none of the 20 children revealed any history of prior epilepsy. Focal-type seizure was noted in 7 children, and a generalized type of seizure was noted in 3 cases upon initial presentation.

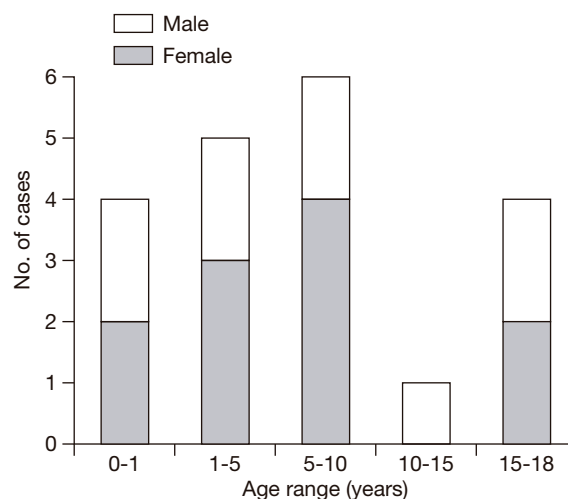


Fig. 1. Age distribution of 20 patients with brain abscess.

Nineteen children had at least one of the symptoms of fever, headache or seizure upon initial presentation.

### Predisposing factors

The most probable predisposing factors for patient brain abscess were able to be identified in 18 of the 20 individuals (90%). Cyanotic congenital heart disease (CCHD) was the most common predisposing factor (7/20; 35%). Three of the 7 children with CCHD had some form of dental infection. The second most common predisposing factor was the presence of some form of otorhinopharyngeal infection, this being detected in 4 patients (20%) [Table 2].

### Location of brain abscess

Fourteen children suffered a single-lesion brain abscess — 5 cases presented in the frontal lobe, 2 in the temporal lobe, 2 in the parietal lobe, 2 in the parieto-temporal lobe, and 1 abscess each was located in the parieto-occipital lobe, the frontotemporal lobe and the thalamus. The remaining 6 children revealed multiple lesions; all of these abscesses were located in

Table 1. Initial symptoms and signs in 20 patients with brain abscess

Symptoms and signs	No. of cases (%)
Fever	15 (75)
Focal neurologic deficits	11 (55)
Seizure	10 (50)
Headache	10 (50)
Nausea/vomiting	8 (40)
Consciousness change	4 (20)
Neck stiffness	2 (10)

**Table 2.** Predisposing factors in 20 patients with brain abscess

Predisposing factor	No. of cases (%)
Cyanotic congenital heart disease	7 (35)
Otorhinopharyngeal infection	4 (20)
Sepsis	3 (15)
Meningitis	3 (15)
Orbital cellulitis	1 (5)
Unknown	2 (10)

the cerebrum. The size of abscesses detected ranged from 0.4 to 5.0 cm in diameter.

### Treatment

Four cases received antibiotic therapy only, the other 16 patients received surgical management. The reasons for not receiving operation included relatively small size of the abscess, improved patient condition following antimicrobial treatment, and/or family's refusal of surgery. In patients who did not undergo surgery, the mean duration of antibiotic treatment was  $60 \pm 30$  days (range, 35-105 days), whereas for those who did undergo surgical treatment in addition to antimicrobial treatment, the mean duration was  $46 \pm 11$  days (range, 28-63 days). The duration of antibiotic therapy was significantly longer in patients who did not undergo surgical intervention ( $p < 0.05$ ).

### Microbiological findings

The 16 individuals who received surgical intervention had abscess pus cultures, 10 of which revealed the

presence of pathogens. *Staphylococcus aureus* was the most common microorganism, being present in 3 patients. Viridans *Streptococcus* was cultured from 2 patients, who were also found to have CCHD with dental infection. *Haemophilus influenzae*, *Enterobacter cloacae*, and *Proteus mirabilis* were detected from 1 patient each. Two patients had polymicrobial infection, 1 revealing *Escherichia coli*, *Klebsiella pneumoniae* and *Bacteroides fragilis* coinfection, and the other *Streptococcus intermedia* and *Pasteurella haemolytica* coinfection.

Microorganism-positive blood culture results were noted in 2 of the 4 patients who did not undergo surgery for their condition. One of these had a skin infection with oxacillin-sensitive *S. aureus* and subsequent sepsis, while the other had *Salmonella* sepsis. The brain abscesses present in these 2 individuals were thought to be due to hematogenous spreading of the infecting microorganisms, and appropriate antibiotics were prescribed according to the results of blood cultures.

### Patient prognosis and neurological sequelae

The only death among the reviewed patients was a 2-month-old girl with *E. coli* sepsis, which later progressed to multiple brain abscesses with subsequent mortality. Among the 19 survivors, 15 revisited our neurological clinic after their discharge and were able to be observed over a period of 2 months to 10 years. Ten patients (67%) developed seizure disorder, and all received anticonvulsant therapy, although 2 cases responded poorly. Data were compared for these 15

**Table 3.** Comparative data for patients with sequelae with and without seizure disorder

Characteristic	Sequelae with seizure disorder (n = 10)	Sequelae without seizure disorder (n = 5)	<i>p</i>
Age (years; mean)	7.8	8.2	1.000
Gender			
Female	5	3	1.000
Male	5	2	1.000
Initial symptoms and signs			
Seizure	7	0	0.026 <sup>a</sup>
Consciousness change	2	0	0.524
Fever	8	3	0.560
Headache	4	5	0.044 <sup>a</sup>
Focal neurologic deficits	7	2	0.329
Vomiting	5	2	1.000
Multiplicity			
Single	7	4	1.000
Multiple	3	1	1.000
Surgery			
Yes	9	4	1.000
No	1	1	1.000

<sup>a</sup> $p < 0.05$ .

patients according to whether or not they developed seizure disorder sequelae (Table 3). There were statistically significant differences between the 2 groups in the incidences of headache and seizure at initial presentation. No significant differences were found in patient age, gender, number of abscesses present, and treatment regimens between the groups. Other sequelae included hemiplegia in 4 patients, mental retardation in 2 patients and bedridden status in 1 patient.

## Discussion

Fever was the most common initial presentation of brain abscess in our study population. This finding is compatible with the results of a number of other analogous studies focusing on younger individuals [5,8-10]. In contrast, fever is not a common symptom for brain abscess in adult patients, occurring in less than 50% of cases in some studies, although its absence should not be used to exclude a diagnosis of brain abscess [8,11]. One study of childhood brain abscess also reported that up to 70% of reviewed cases were afebrile, and it may be that such an outcome is due to children exhibiting a slow or inactive host reaction to systemic infection [12]. Focal neurological deficits, seizure and headache are also commonly reported presentations in children, and were noted in more than half of our patients, although the reported rates of such symptoms differ between adults and children. For the adults, headache would appear to be the most common symptom [6,8,11]. The reason for such a difference pertains to poor language expression in children. The classic triad of headache, fever and focal neurological deficits was present in only 25% to 31% of patients in previous reports of Taiwanese adult patients [6,7], and was found in only 1 of our patients.

In this study, 35% of patients had CCHD as their underlying medical condition. Although several predisposing factors have been reported to be causally related to brain abscess, CCHD is the most common, being implicated in about 25% to 46% of such cases [13-16]. Several probable mechanisms for the formation of brain abscesses in children with CCHD have been postulated previously [14,15,17,18]. Otorhinopharyngeal or dental infections were frequently associated with the presence of brain abscesses, not only in our study but also in other adult-derived data. Immunosuppression of study participants has been increasingly reported in children, although this was not noted in our study [16]. Unlike the adult experience of brain abscess in Taiwan, no

children in this study had concomitant liver abscess and/or diabetes mellitus [6,7].

A number of studies have reported that staphylococci, streptococci, and *Proteus* spp. are the most common aerobic microorganisms, while anaerobic streptococci and *Bacteroides* spp. are the most common anaerobic pathogens in children with brain abscesses [12,19-23]. Only 1 of our patients had an anaerobic pathogen, *B. fragilis*, in contrast to the report in 1965 by Raimondi et al, in which anaerobic streptococci were the most commonly isolated agents from brain abscess exudates among children with congenital heart disease [24]. A previous study from Taiwan by Kao et al found that there were no principal or dominating microorganisms in brain abscess patients less than 18 years of age [6]. Nonetheless, our results may provide some insight for the choice of empirical antibiotics for children with brain abscesses. *K. pneumoniae* has been regarded as an important pathogen for Taiwanese adults, but is rare in Taiwanese children [6,7].

The incidence of seizure disorder sequelae (67%) noted in our study was greater than in other studies, which have reported rates in the range 16% to 65% [2,5,25]. However, it may be that patients with seizure disorder sequelae were more likely to choose to be followed up at our hospital compared to individuals suffering from other sequelae, such as limb weakness or mental retardation. Seizure disorder sequelae developed more commonly in patients with the initial presentation of seizure (Table 3) [ $p < 0.05$ ]. In this regard, more severe local inflammation or infection might result in a more severe local cerebral reaction. However, individuals presenting with headache as the initial symptom had a lower incidence of seizure disorder sequelae than those without headache. In addition, heightened awareness of the potential for central nervous system sequelae among patients with headache might influence results in this setting. Clearly, further investigation incorporating a greater number of case studies is necessary in order to clarify these issues.

In this study, CCHD was shown to be the most common predisposing factor for brain abscess. The classic triad of headache, fever and focal neurological deficit typically seen in adults with brain abscess would appear to be rare in children. Our results indicate a relatively high level of neurological sequelae in children with brain abscess. In this clinical setting, the initial presentation of seizure attack indicates an increased likelihood of further seizure disorder sequelae.

## References

1. Feigin RD, Cherry JD, eds. Textbook of pediatric infectious disease. 4th ed. Philadelphia: WB Saunders; 1997:430-4.
2. Gregory DH, Messner R, Zinneman HH. Metastatic brain abscesses. A retrospective appraisal of 29 patients. *Arch Intern Med.* 1967;119:25-31.
3. Fischer EG, McLennan JE, Suzuki Y. Cerebral abscess in children. *Am J Dis Child.* 1981;135:746-9.
4. Jadavji T, Humphreys RP, Prober CG. Brain abscesses in infants and children. *Pediatr Infect Dis.* 1985;4:394-8.
5. Sáez-Llorens XJ, Umaña MA, Odio CM, McCracken GH Jr, Nelson JD. Brain abscess in infants and children. *Pediatric Infect Dis J.* 1989;8:449-58.
6. Kao PT, Tseng HK, Liu CP, Su SC, Lee CM. Brain abscess: clinical analysis of 53 cases. *J Microbiol Immunol Infect.* 2003;36:129-36.
7. Ni YH, Yeh KM, Peng MY, Chou YY, Chang FY. Community-acquired brain abscess in Taiwan: etiology and probable source of infection. *J Microbiol Immunol Infect.* 2004;37:231-5.
8. Yang SY. Brain abscess: a review of 400 cases. *J Neurosurg.* 1981;55:794-9.
9. Hegde AS, Venkataramana NK, Das BS. Brain abscess in children. *Childs Nerv Syst.* 1986;2:90-2.
10. Moss SD, McLone DG, Arditì M, Yogev R. Pediatric cerebral abscess. *Pediatr Neurosci.* 1988;14:291-6.
11. Chun CH, Johnson JD, Hofstetter M, Raff MJ. Brain abscess. A study of 45 consecutive cases. *Medicine (Baltimore).* 1986;65:415-31.
12. Tekkök IH, Erbençi A. Management of brain abscess in children: review of 130 cases over a period of 21 years. *Childs Nerv Syst.* 1992;8:411-6.
13. Aebi C, Kaufmann F, Schaad UB. Brain abscess in childhood — long-term experiences. *Eur J Pediatr.* 1991;150:282-6.
14. Takeshita M, Kagawa M, Yonetani H, Izawa M, Yato S, Nakanishi T, et al. Risk factors for brain abscess in patients with congenital cyanotic heart disease. *Neurol Med Chir (Tokyo).* 1992;32:667-70.
15. Yang SY. Brain abscess associated with congenital heart disease. *Surg Neurol.* 1989;31:129-32.
16. Goodkin HP, Harper MB, Pomeroy SL. Intracerebral abscess in children: historical trends at Children's Hospital Boston. *Pediatrics.* 2004;113:1765-70.
17. Piper C, Horstkotte B, Arendt G, Strauer BE. Brain abscess in children with cyanotic heart defects. *Z Kardiol.* 1994;83:188-93. [Article in German].
18. Parikh S, Bharucha B, Kamdar S, Kshirsagar N. Polymorphonuclear leukocyte functions in children with cyanotic and acyanotic heart disease. *Indian Pediatr.* 1993;30:883-90.
19. Beller AJ, Sahar A, Praiss I. Brain abscess. Review of 89 cases over a period of 30 years. *J Neurol Neurosurg Psychiatry.* 1973;36:757-68.
20. Nielsen H, Gyldensted C, Harmsen A. Cerebral abscess. Aetiology and pathogenesis, symptoms, diagnosis and treatment. A review of 200 cases from 1935-1976. *Acta Neurol Scand.* 1982;65:609-22.
21. Mampalam TJ, Rosenblum ML. Trends in the management of bacterial brain abscess: a review of 102 cases over 17 years. *Neurosurgery.* 1988;23:451-8.
22. Stephanov S. Surgical treatment of brain abscess. *Neurosurgery.* 1988;22:724-30.
23. Ibrahim AW, al-Rajeh SM, Chowdhary UM, Ammar A. Brain abscess in Saudi Arabia. *Neurosurg Rev.* 1990;13:103-7.
24. Raimondi AJ, Matsumoto S, Miller RA. Brain abscess in children with congenital heart disease. I. *J Neurosurg.* 1965;23:588-95.
25. Wright RL, Ballantine HT Jr. Management of brain abscesses in children and adolescents. *Am J Dis Child.* 1967;114:113-22.